Dentoalveolar Surgery Complications

Maria Franco Echevarria, MD, DMD, MSc, FRCDC
Assistant Professor. Undergraduate Program Director
Oral and Maxillofacial Surgery

Faculty of Dentistry
University of Toronto
maria.francoechevarria@utoronto.ca

Objectives

1. Existence
2. Prevention
3. Management

Dentoalveolar Surgery Complications

Intraoperative Complications

- Extraction of wrong tooth
- Extracted tooth/segment displacement
  - Adjacent tissues
  - Aspiration / Ingestion
- Soft tissue injuries
- Damage to adjacent teeth
- Root fracture
- Oro Antral Communication
- Fracture of alveolar process / tuberosity
- Fractured mandible
- Bleeding

Postoperative Complications

- Infection
- Dry socket
- Subperiosteal abscess
- Neurological complications
- Bleeding
- TMJ pain

Intraoperative Complications

Extraction of Wrong Tooth

Intraoperative Complications



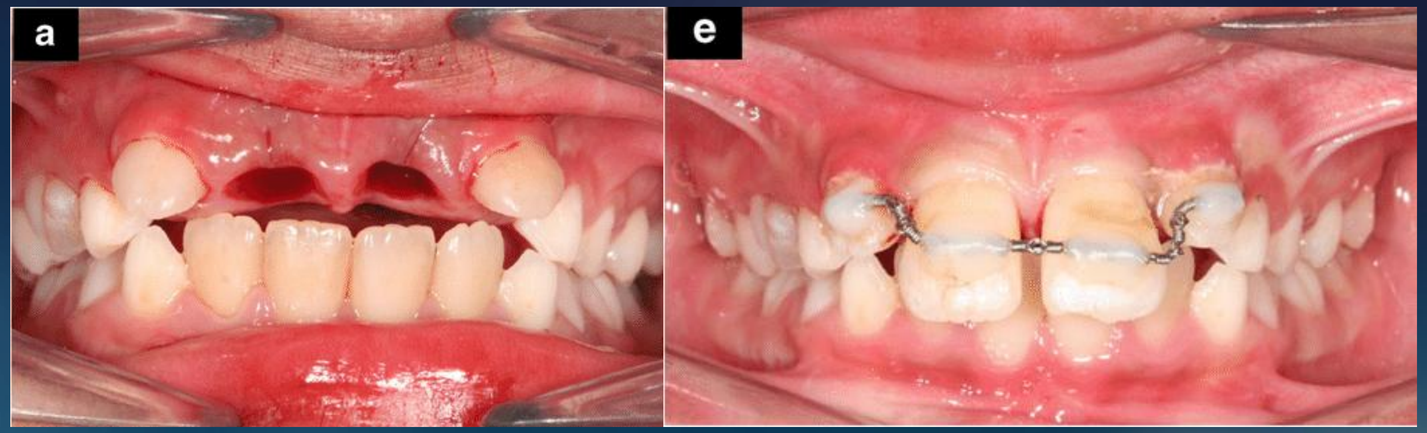

Panic moment!

Miscommunication between treating practitioners
Distraction - Mental lapse

Management
- Inform patient
- If realized on the spot – **treat as avulsion**
- Reimplant – immobilize – check for vitality later

Confirm from previous notes
Count twice
Be alert

Extracted tooth/tooth segment displacement

Intraoperative Complications

Floor of the mouth

Buccal vestibule

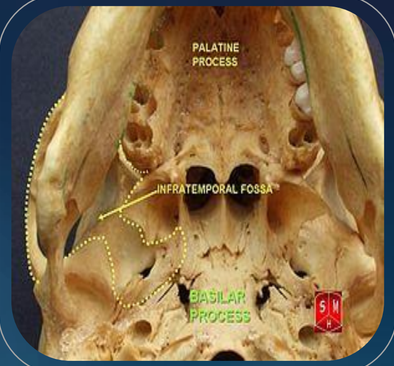

Infratemporal fossa

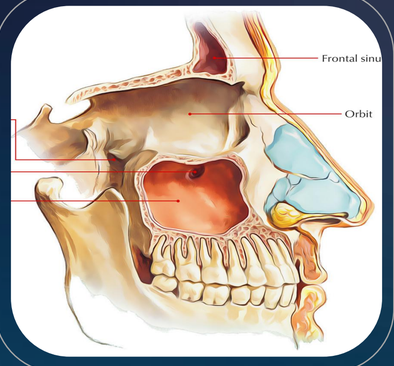

Maxillary sinus

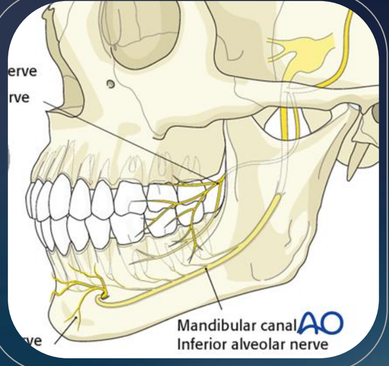

IAN Canal

- Poor planning / technique
- Inadequate flap retraction
- Blind surgical maneuvers
- Too much force
- Avoid apical pressure
- Protect disto-buccal space in the maxilla

Extracted tooth/tooth segment displacement – Floor of the Mouth

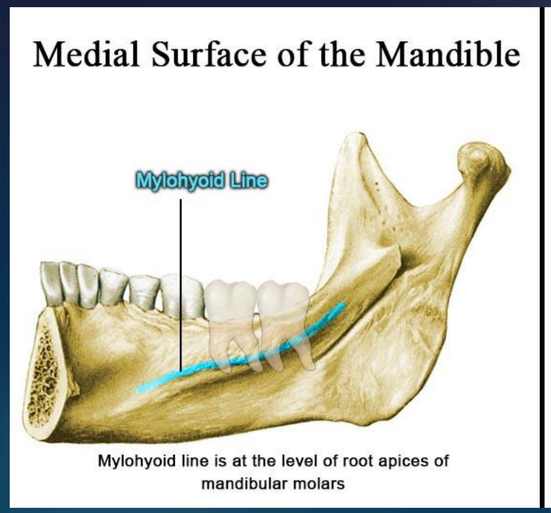

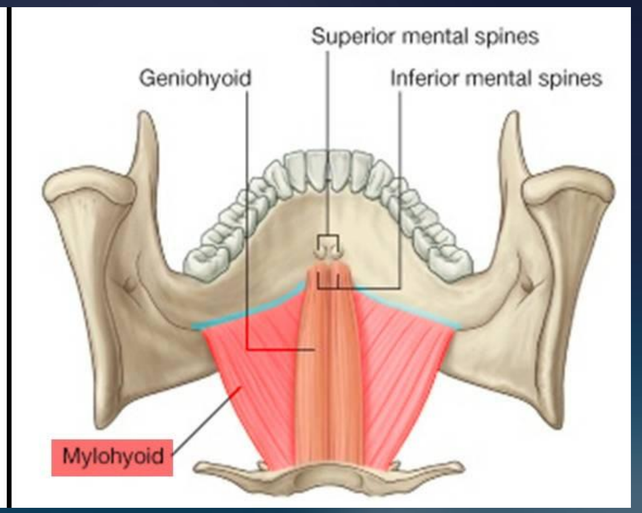

Look carefully into surgical area, bone window may be obvious
Occlusal films could help visualizing the fragment
Digital pressure in area, palpation of segment

Upwards "milking" of segment
If unsuccessful put patient on antibiotics – refer

Mylohyoid Muscle Determines Sublingual vs Submandibular
Mesial root -above, Distal root-below mylohyoid

Surgeon likely to wait for 2 -6 weeks for **fibrosis to take place** – workup with CT for proper location of segment – surgical removal

If root fragment is small and no associated with pathology and asymptomatic, may elect to observe

Extracted tooth/tooth segment displacement – Buccal Vestibule

Most likely maxilla

Most likely superficial **subperiosteal location**
Palpate mucosa in area – try to locate segment

Extent flap reflection to reach if segment palpated
Alternatively incise mucosa and remove
Be careful with Stensen duct

If unsuccessful **put pt. on antibiotics and refer**

Extracted tooth/tooth segment displacement – Infratemporal Fossa

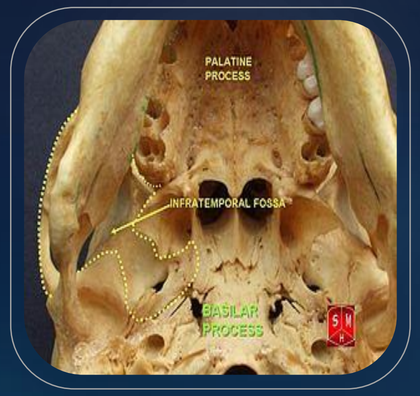

Likely the whole **maxillary third molar**

Due to poor technique / **blind attempt** to remove

Minimal attempt should be made
Enlarge flap, dissect subperiosteally
Do try to fish it out, you will push it further
If unable, close and **put patient on antibiotics-refer**

Surgical retrieval in 3-4 weeks after CT location

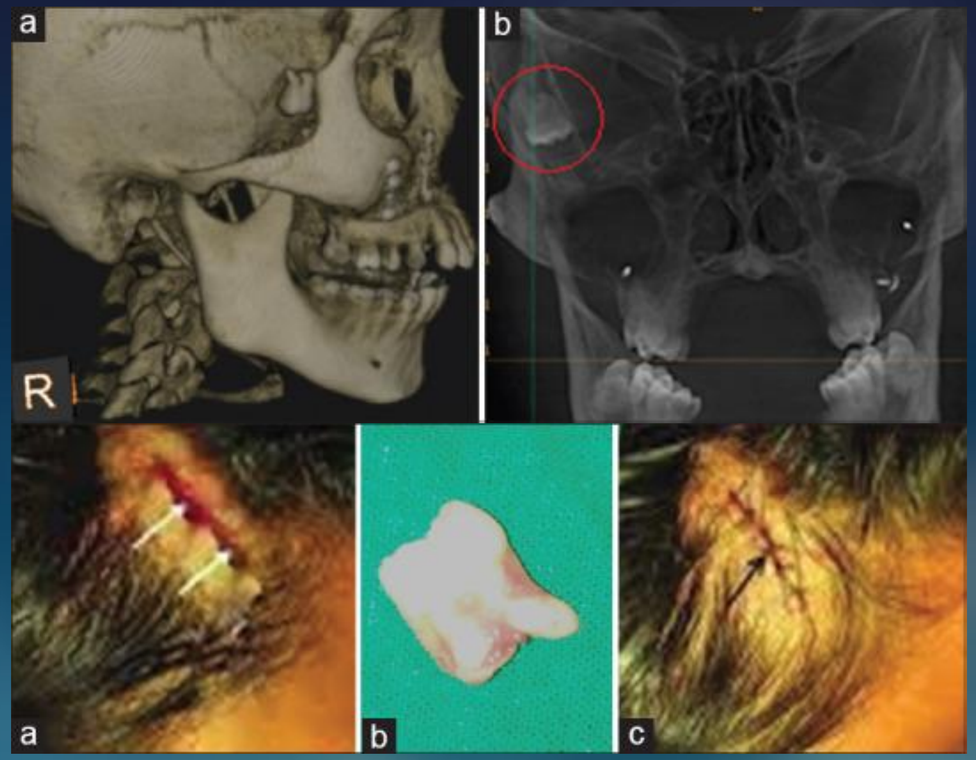

A broad retractor that rests on the bone above the level of the tooth or root

Extracted tooth/tooth segment displacement – Maxillary Sinus

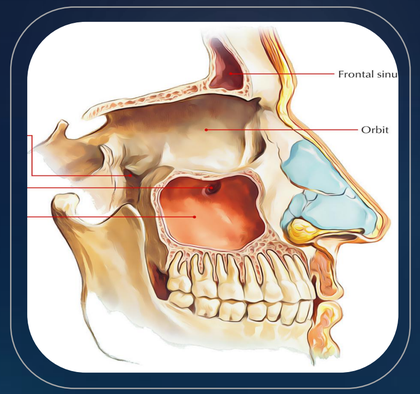

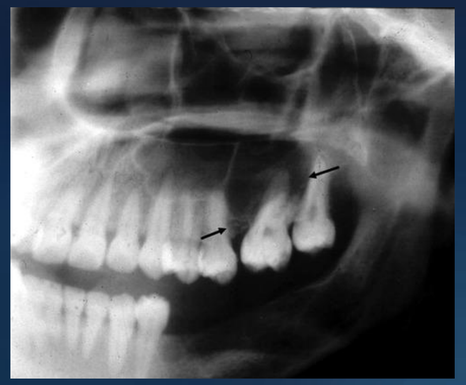

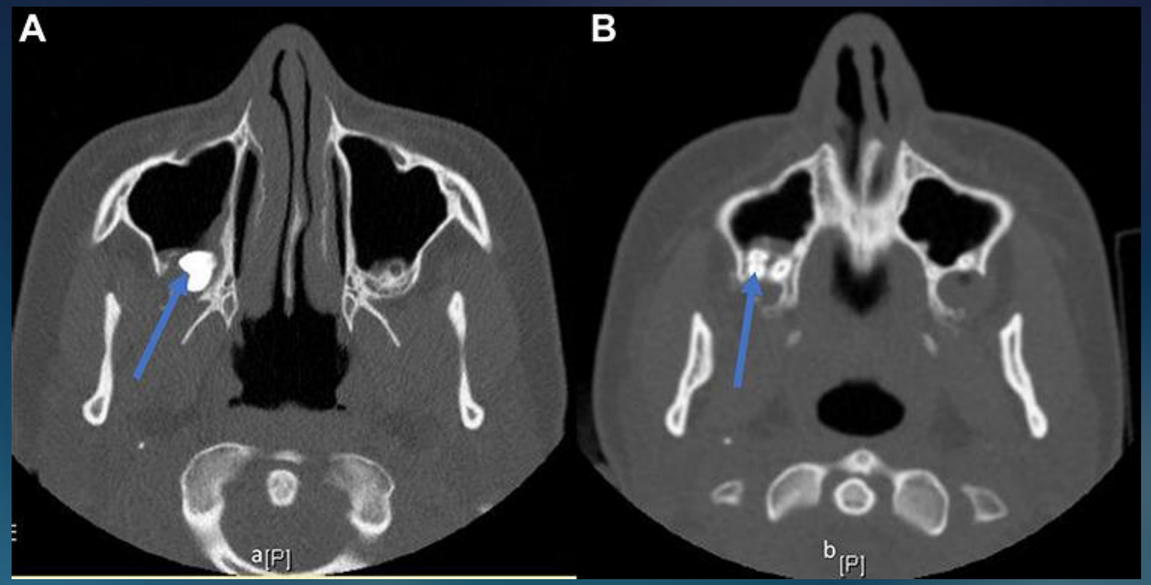

Best management is **prevention**

Identify risk by carefully assessing radiographs for root location and pneumatization of the maxillary sinus
Inform patient if risk is high

Start surgically from the onset
Avoid vertical upward forces on fractured segments

Tooth segment: palatal root of maxillary first molar most common 75-78%
Whole tooth most commonly displaced upper third molar

Extracted tooth/tooth segment displacement – Maxillary Sinus

Radiograph → Try to retrieve → Antibiotic → Refer for surgery

Sinus precautions + antibiotics

Amoxicillin/clavulanic acid 500mgr po TID X 15days
Cephalosporins, Clindamycin
Erythromycin, Clarithromycin

Surgeon could remove it through a lateral sinus approach, Caldwell-Luc approach, or endoscopic sinus surgery

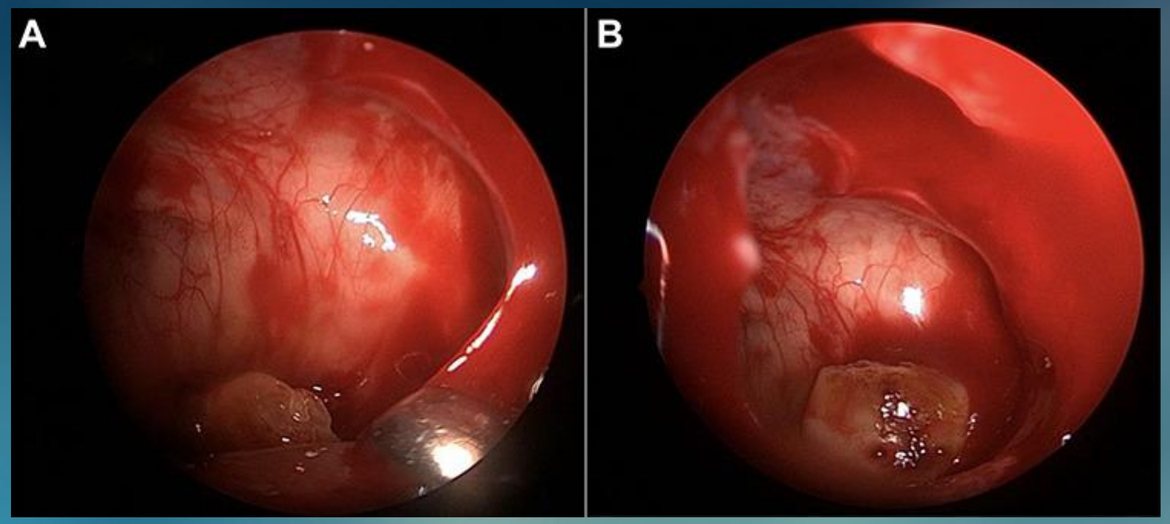

Extracted tooth/tooth segment displacement – Maxillary Sinus

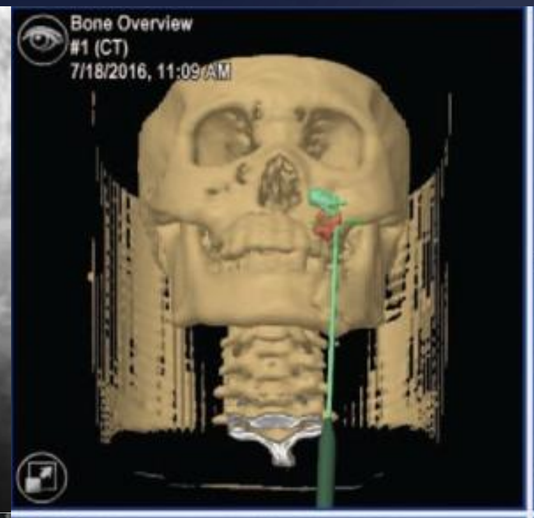

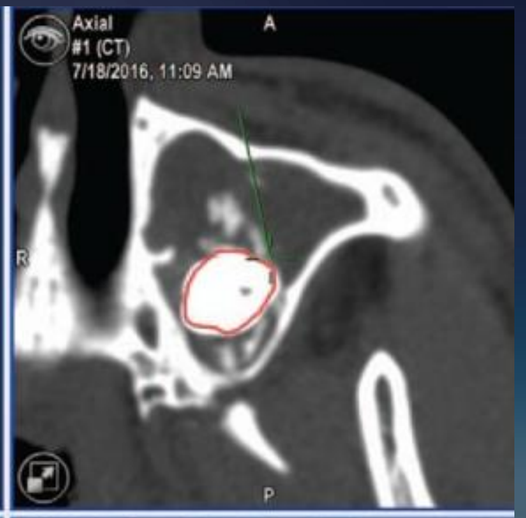

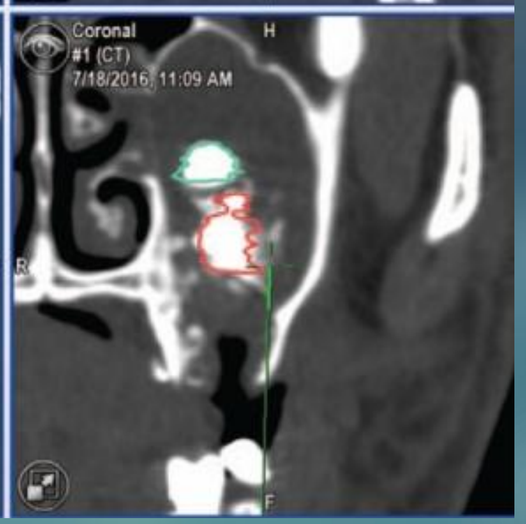

Extracted tooth/tooth segment displacement – Maxillary Sinus Approaches

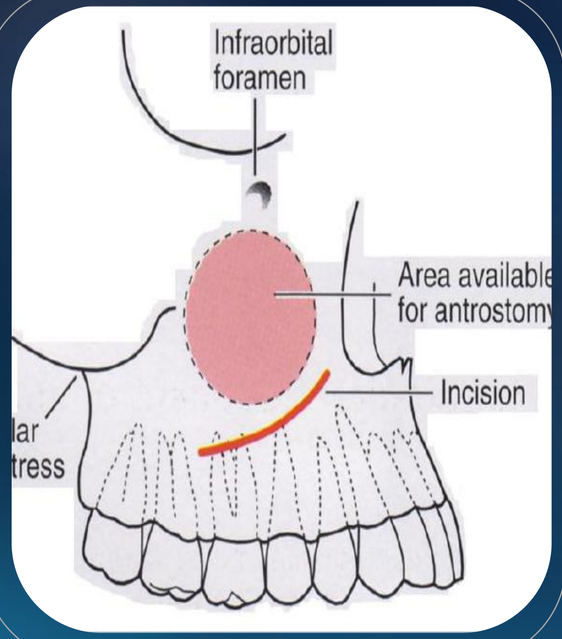

Cadwell-Luc

Bony window created at the anterior maxillary wall
Visualization of the maxillary sinus
Careful attention to infraorbital nerve

Transalveolar approach

Extending the opening in the extraction socket and removal of buccal bone beyond the apex
Closed by an advancing buccal flap

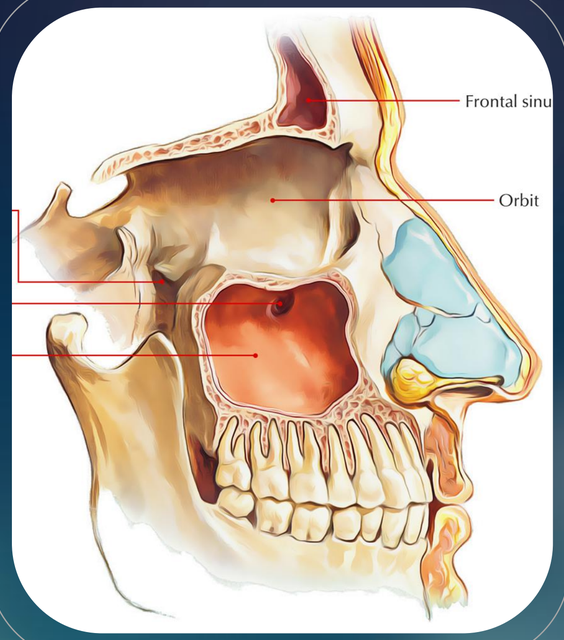

Endoscopic sinus surgery

Minimizing approach
Sometimes difficult to retrieve if big fragments in the sinus

Extracted tooth/tooth segment displacement – Inferior Alveolar Canal

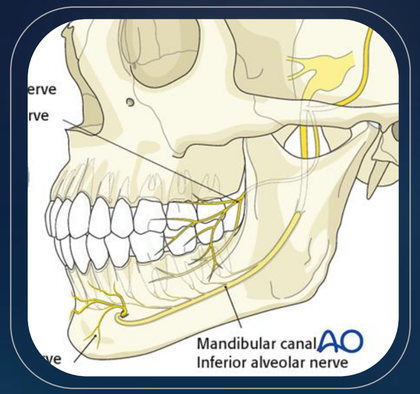

Take a radiograph of the fragment

Gentle attempt to remove it, if it does not work:

- Delayed removal
- Antibiotics
- If no signs of infection or parestesia the fragment might be left in place

Pay attention to the patient symptoms
More common with posterior teeth

Aspiration

Intraoperative Complications

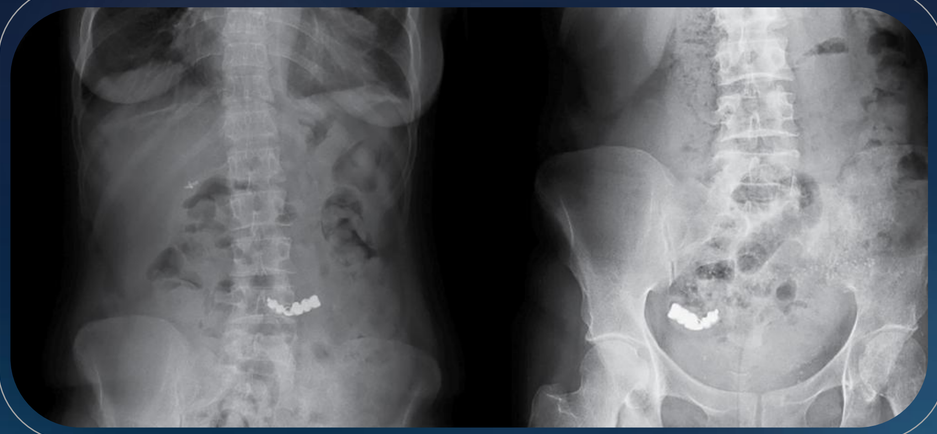

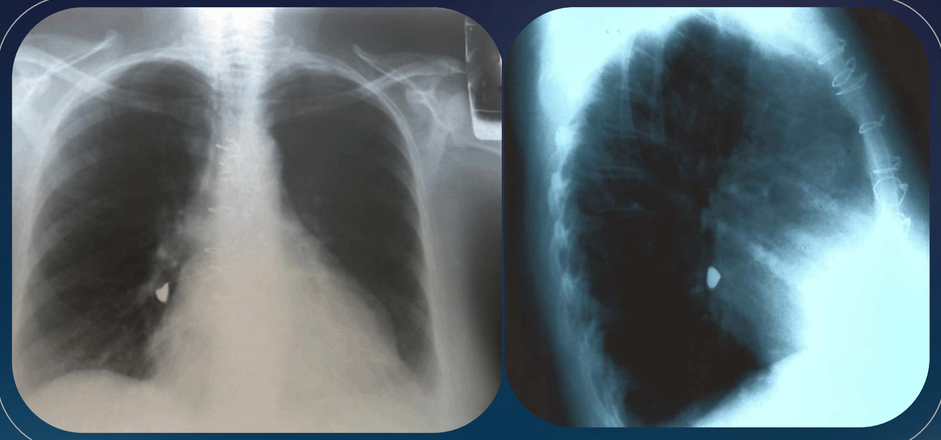

Smooth passage through pharynx
Awake patient “knows it”

Violent passage through pharynx/larynx
Severe gag and cough reflex in awake patient
Laryngeal obstruction unlikely due to small size
Less (obtunded) reaction if patient sedated

Both due to:
Wrong technique, attention lapse
Lack of pharyngeal curtain (esp. sedated patient)

Management:
If laryngeal obstruction, Heimlich, ACLS protocol. Emergency cricothyrotomy if worsening
Immediate referral to ER for chest X rays and abdominal xrays
Bronchoscopy if aspirated

Soft Tissue Injuries

Intraoperative Complications

Accidental punching
Soft tissue tear
Strech or abrasion injury
Flap edges torn due to excessive pulling
Puling on teeth with soft tissues attached
Pressure to adjacent soft tissue (Minnesota)

Due to careless/poor technique :
adequately sized flap and small amount of retraction

Abrassion injury: rotatin shank of the bur on soft tissue

Assess extent
Debride area
Suture tissues back
Consider antibiotics
If abrasion, consider covering with antibiotic ointment

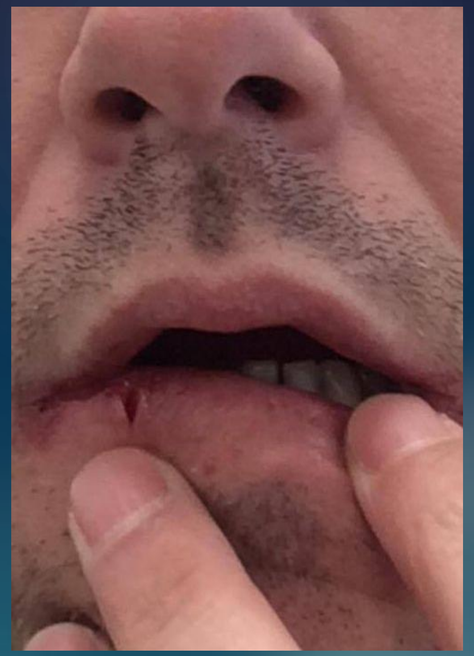

Tearing of mucosal flap is the most common soft tissue injury

Soft Tissue Injuries

Intraoperative Complications

Tearing mucosal flap:

The cause usually is an inadequately sized flap

How to prevent?

- Create enough flap
- Use small amount of retraction force
- Use releasing incisions if needed
- Do not put releasing incisions on buccal canine
- Avoid palatal flaps in the area of the GPA
- Never release in lingual mandible
- Suture carefully

Strech and abrasion injury:

Most frequent at the corner of the lip

Usually from the rotating shank
Cover with vaseline or antibiotic ointment
5-10 days to heal

Damage of Adjacen Teeth

Intraoperative Complications

Adjacent teeth with
- Large restorations
- Caries
- Recurrent decay
- Temporary or permanent crowns
- Temporary restorations
- Mobility
- Compromised teeth

Due to careless/poor technique
Failure to recognize teeth at risk
Improper use of dental elevators

If it happens:
Notify patient
Re-cement crown
Temporize tooth – plan to treat it
Provide alternatives/remedial actions to pt

Root Tip Fracture

Intraoperative Complications

Common causes:

- Excessive forces
- Inadequate technique
- Inadequate separation of roots
- Root anatomy
- Bone quality

Prevention:

Proper surgical technique

+

Recognition of teeth at risk for root fracture

- Multirooted posterior teeth
- Dilacerated root
- Thin root
- Widely spaced roots

Root Tip Fracture

Intraoperative Complications

If most of the root is retained needs to be removed

If root tip (2-3mm) has been fractured, leave if:

- Small fragment less than 3mm
- Fragment deep in bone
- No pathology
- No infection
- No mobility
- High risk surgery

Do not leave if

- Implant anticipated, necrotic or infected, mobile

ALWAYS INSTRUCT THE PATIENT OF THE SITUATION
TAKE A RADIOGRAPH IN THE MOMENT AND FOLLOW-UP
WITH CLINICAL AND RADIOGRAPHIC EXPLORATIONS

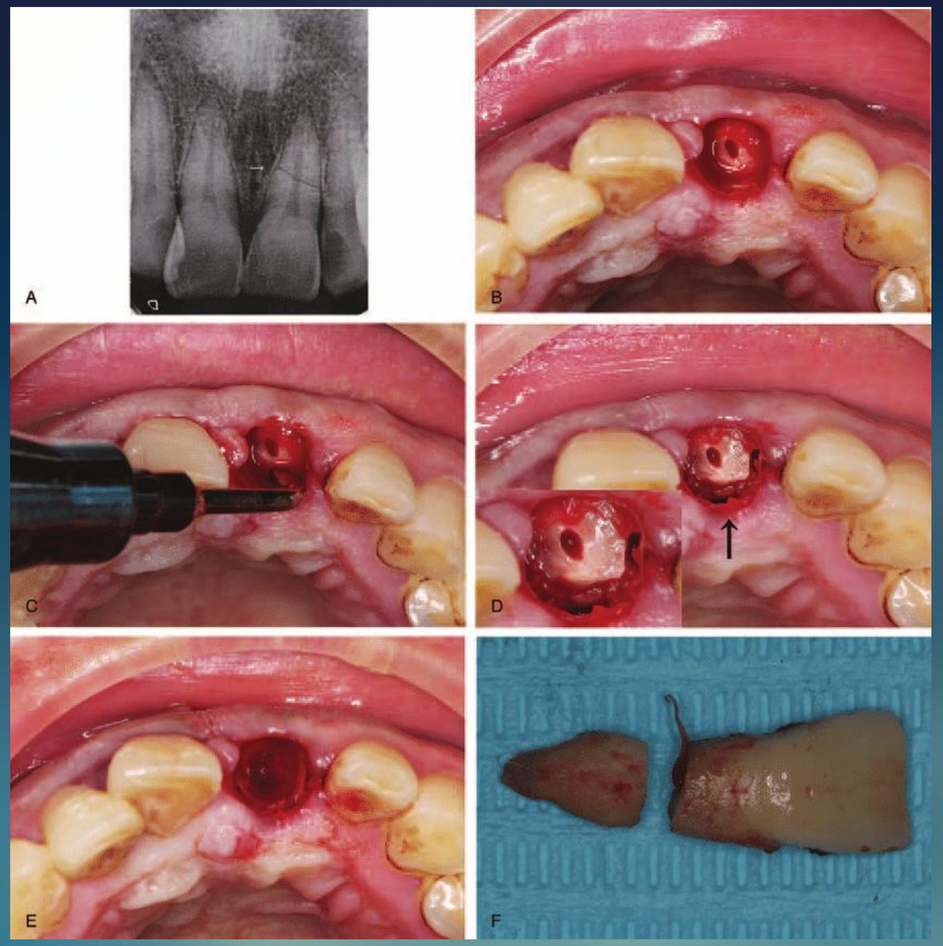

Oro Antral Communication

Iintraoperative Complications

Diret visualization or with mirror
Symptoms described by patient
Valsalva maneuver is controversial

Generally, if patient has a communication that is significantly large enough to manage it, you will see it

Causes

- Root proximity to maxillary sinus
- Bad surgical technique
- Large tuberosity fracture
- Pneumatized sinus
- Pre existing periapical pathology
- Preexisting sinusitis
- Traumatic extraction
- Pushing root into sinus
- Iatrogenic/accidental

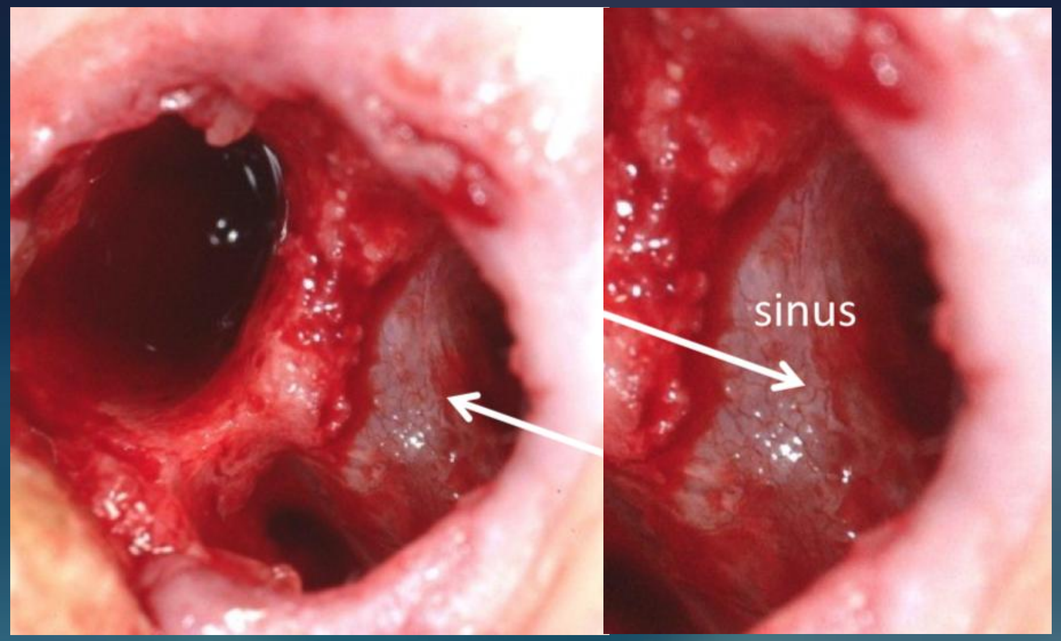

Extracted tooth/tooth segment displacement – Maxillary Sinus

SINUS PRECAUTIONS

- No nose blowing
- Open-mouthed sneezes
- No spitting
- No smoking
- No straw
- No exercise
- Medications
  - Pseudoephedrine
  - Antibiotics: Clavulin
  - Saline nasal spray

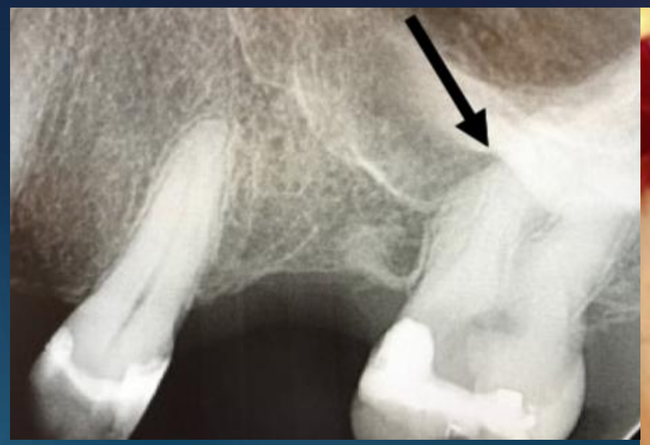

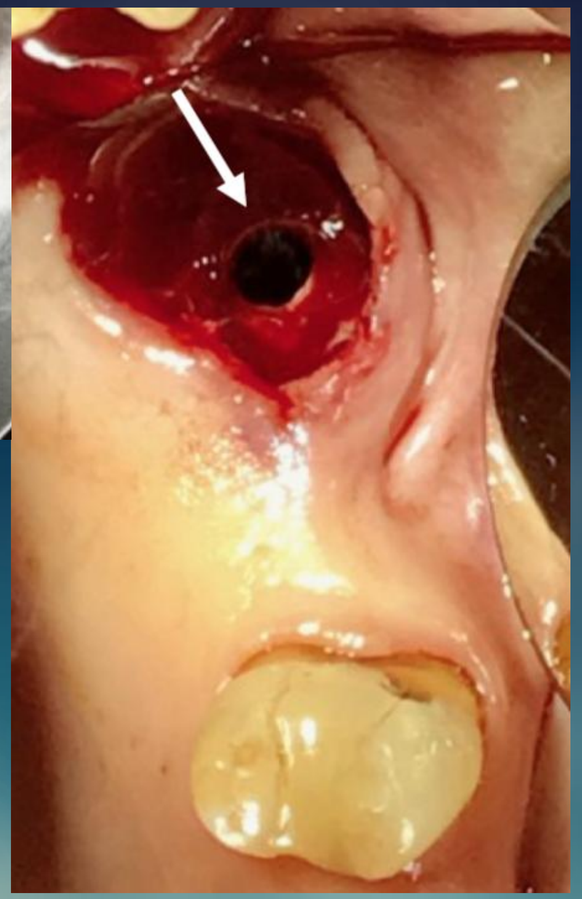

OAC? Sinus precautions

Oro Antral Communication

Intraoperative Complications

If perforation suspected, don't enlarge probe, or irrigate

- Less than 2 mm: suture to support clot, sinus precautions
- 3-6 mm: Gelfoam, figure 8 suture, sinus precautions
- Over 6 mm: tension-free primary closure

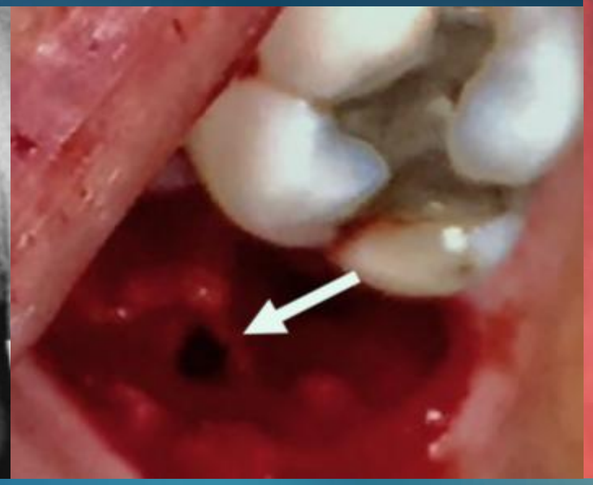

Oro Antral Communication

Iintraoperative Complications

Fistula present:

- Remove fistula
- Separate/push sinus membrane up
- The epithelium needs to be reflected off the bone, upwards
- Advance a buccal flap on top of opening
- Suture
- Antibiotics
- Sinus precautions
- Follow-up

Fistula is a permanent abnormal passageway between two organs in the body or between an organ and the exterior of the body

Sinus tract is a narrow, elongated channel in the body that allows the escape of fluid

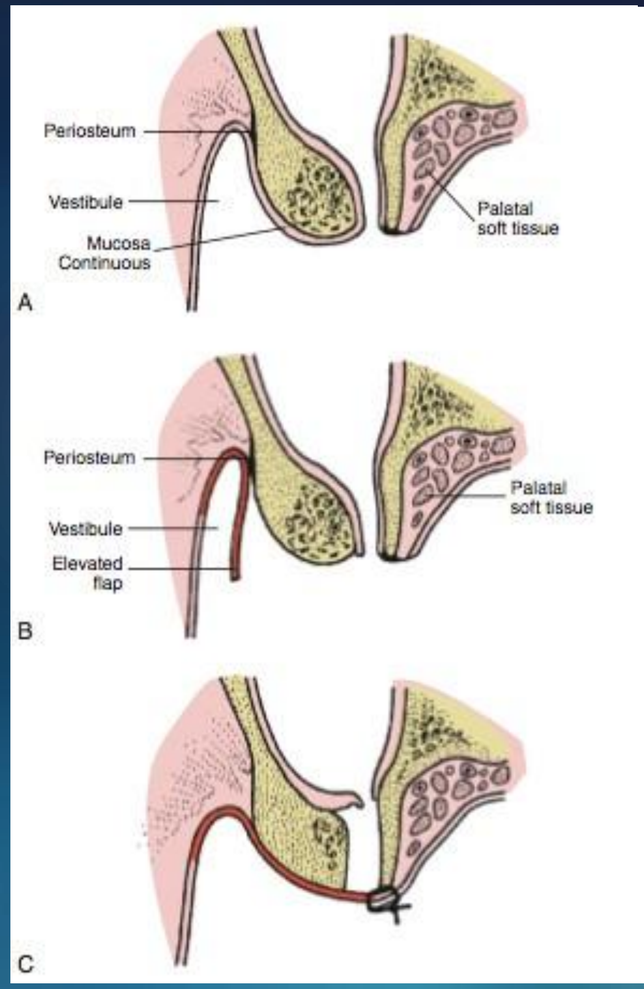

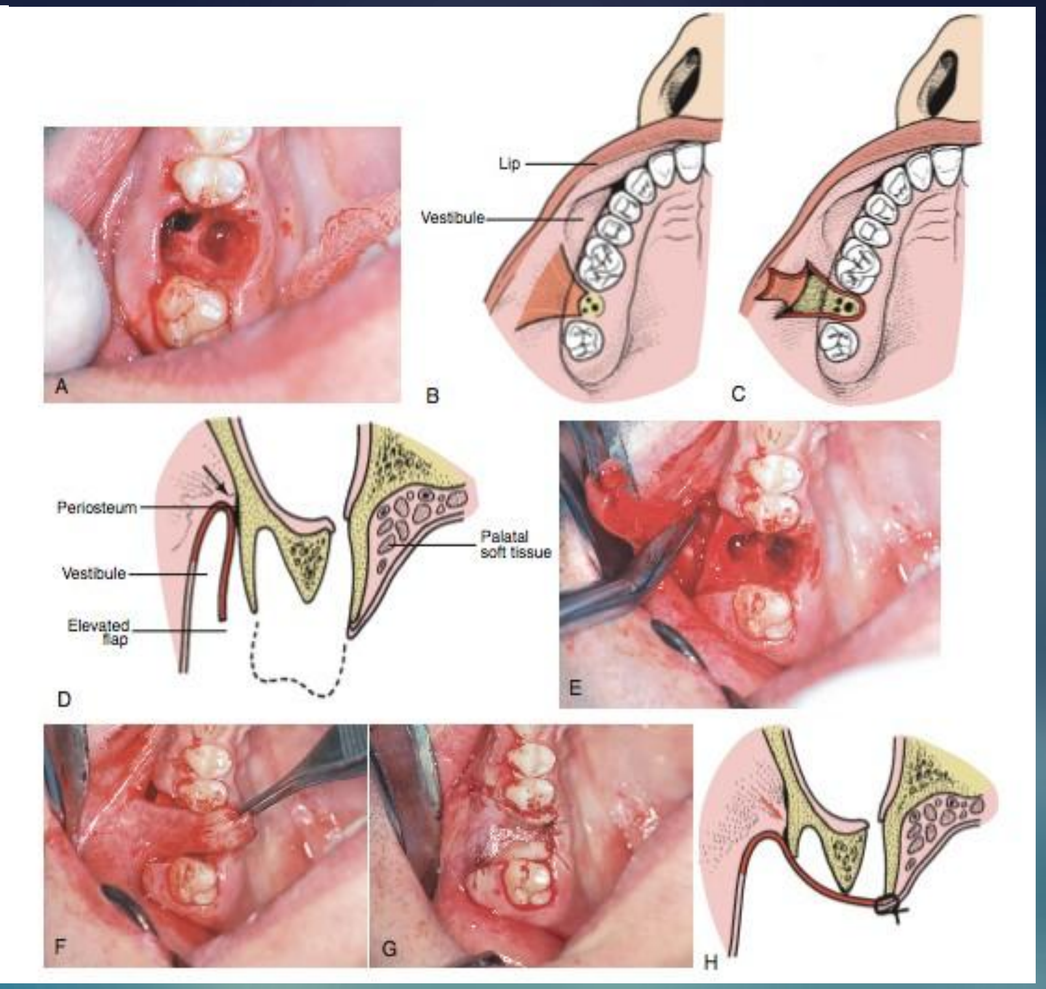

Oro Antral Communication

Iintraoperative Complications

Buccal advancement flap:

It is a vestibular flap that includes papilla and has a large base

To mobilize it we need to perform scoring of the periosteum

Sometimes even buccal bone needs to be removed in favor of a passive water tight suture

Sometimes it can create hematoma postop and decrease the vestibular height

Another option is a rotated palatal flap but it is frequently used for oro-nasal communications

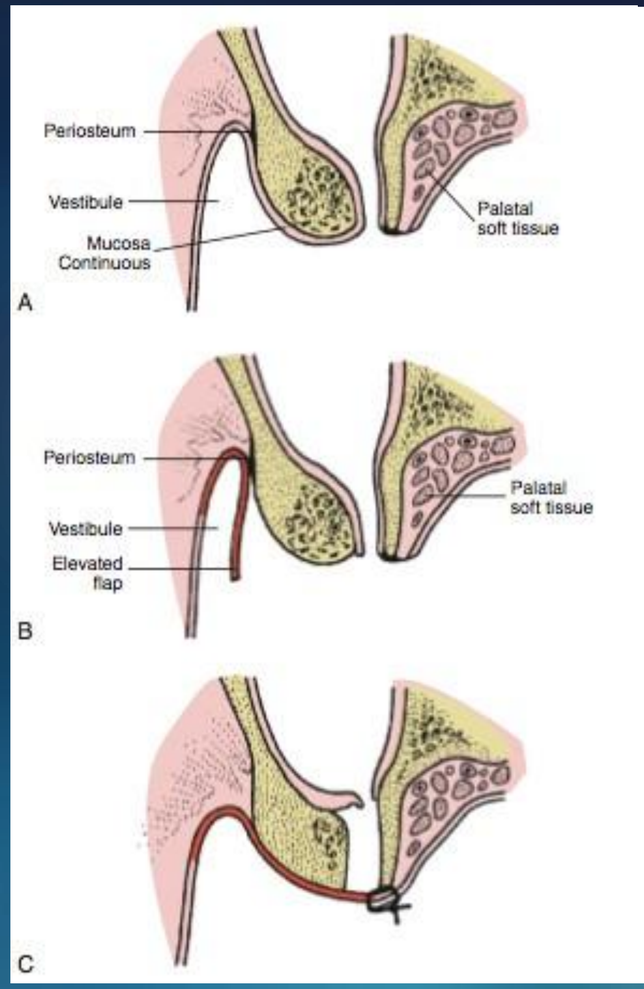

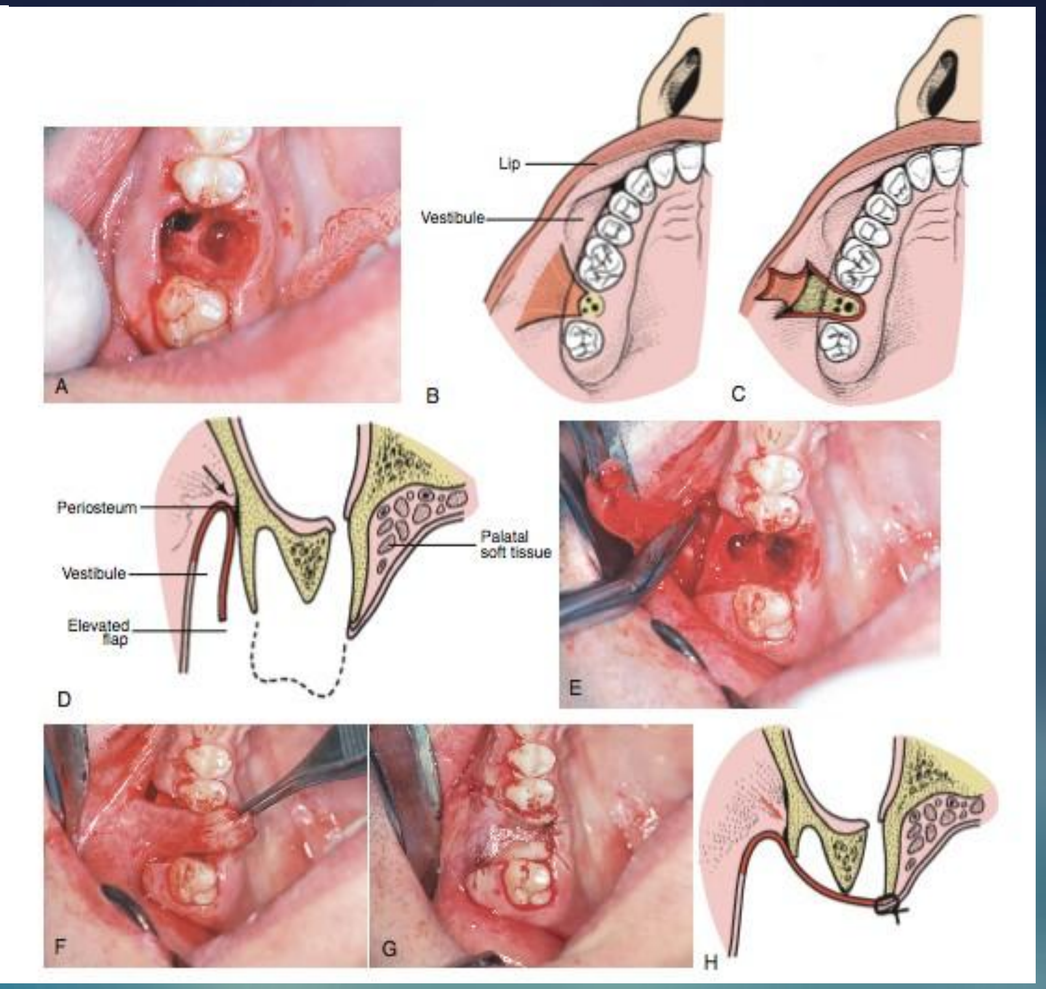

Fracture of the Alveolar Process / Tuberosity

Intraoperative Complications

<u>ALVEOLAR PROCESS:</u>
Try to separate attached to periosteum bone from tooth
If successful remove tooth place flap/attached bone back
If not successful remove bone/tooth
Suture
Antibiotics – follow up

<u>TUBEROSITY (SINUS WALL):</u>
Try to separate the tooth from the surrounding bone, and do not pull on the bone so it maintains periosteum attachment

If yes: stabilized the bone fragment by suturing the mucosa

If it cannot be separated:
Elevate a full thickness periosteal flap on buccal and separate palata, closure and check for OAC

Or if not splint and wait 6-8 w and then perform a surgical extraction, bue for this we need no pain prior to extracton, no pathology and no infection

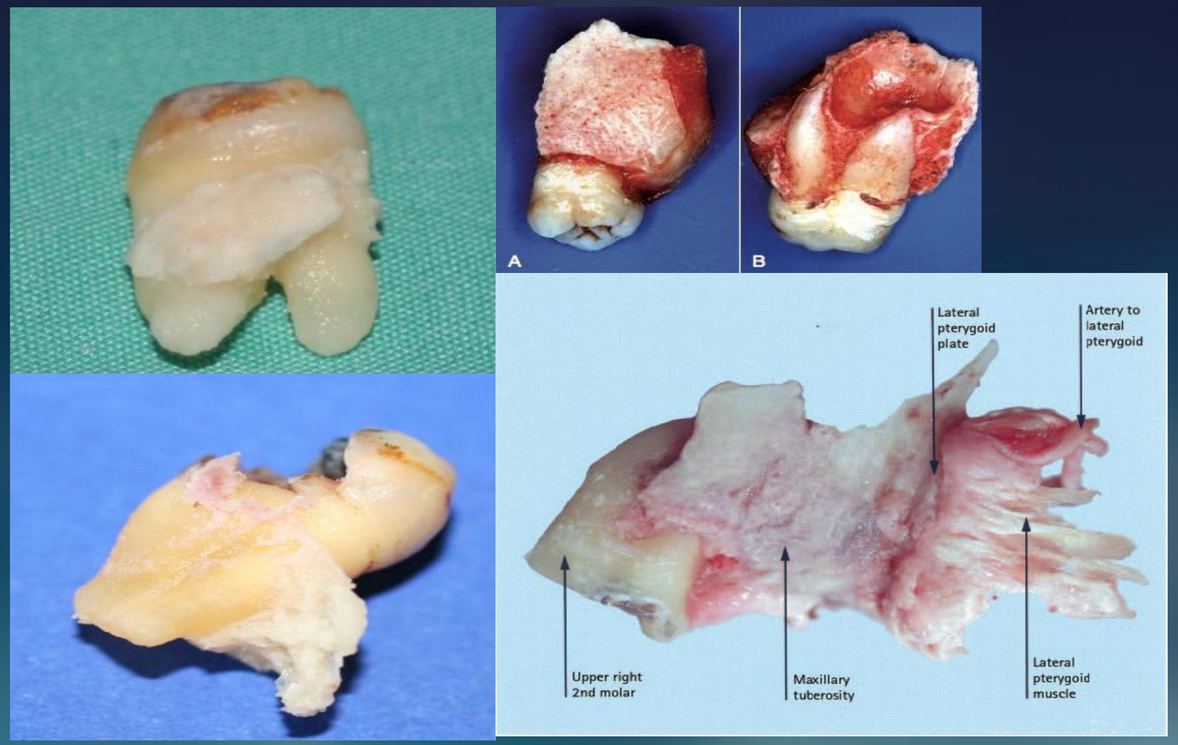

Upper third molars
Specially if single and isolated
Bulbous, divergent or dilacerated roots
Age

Mandible Fracture

Intraoperative Complications

0.0034-0.0075%
They can occur during procedure or during the first 4 weeks
Postoperative are most frequent in the second and third weeks

Iatrogenic most of the time
Unless preexisting pathology like third lower molars

Recognition: fracture line, mobile alveolar segment, mobile mandibular segment, malocclusion, radiograph

Management: from soft diet to ORIF

TMJ injury from not supporting mandible when extracting teeth in mandible

Elderly patient
Atrophic mandible
Mandible with intra-bony lesion

Bleeding

Intraoperative Complications

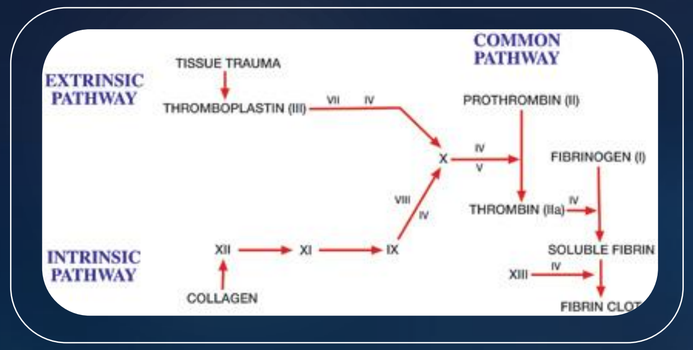

A result of direct trauma/severing of vessels during surgery

Capillary bleeding stops shortly after trauma
Larger vessels may require:

- Pressure
- Cauterization
- Surgicel
- Bone crushing
- bone wax
- Ligation

Intraop bleeding rarely an issue in normal patients

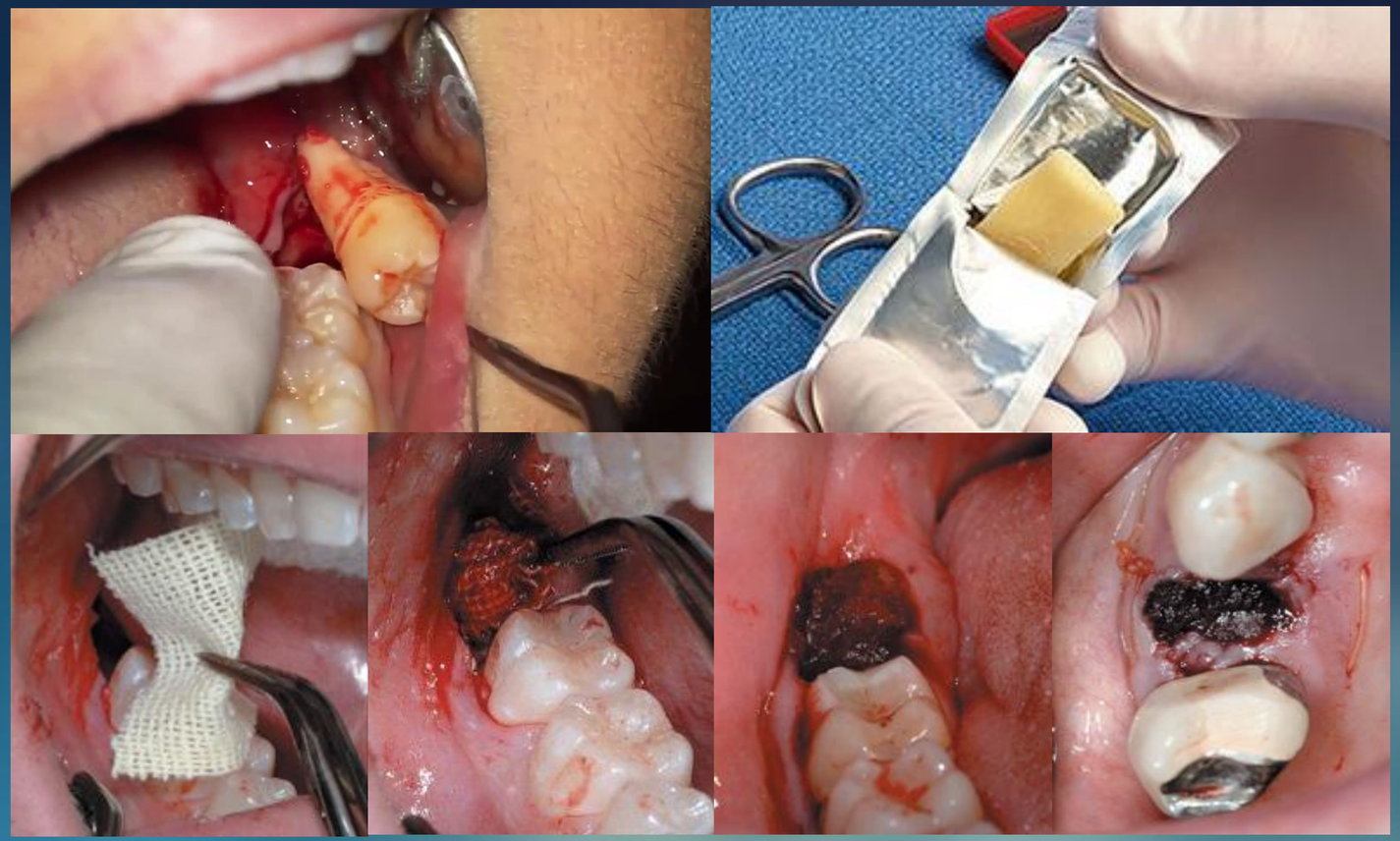

Postoperative Complications

Infection

Postoperative Complications

Inflammatory reaction triggered by local bacterial activity.

Incidence 0.8%-4.2%

Oral cavity wound classified as “clean-contaminated”, Class II SSI risk< 10%

Inflamed operculum without pus collection makes it a “contaminated” wound, Class III, SSI risk 20%

Operculum with pus collection is a ”dirty” wound, Class IV SSI risk up to 50%

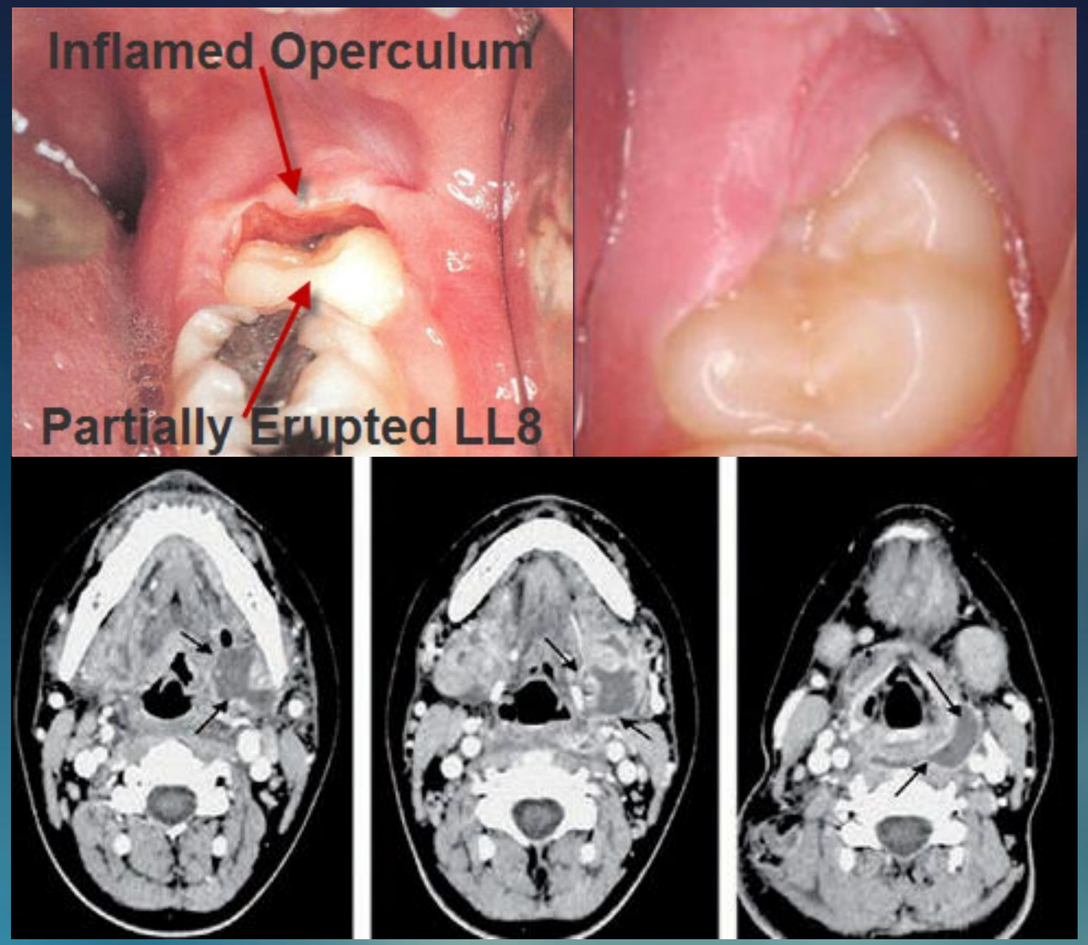

Infection

Postoperative Complications

Pain
Swelling
Trismus

Double peak!!!!

Infection!!!

Timing of this second peak is usually +4 PO day

Risk Factors
- Dirty woung pre op
- Extent of surgical trauma
- Old/Medically compromised patients
- Surgeon's experience (handling of tissues, length of procedure)

Infection

Postoperative Complications

There is moderate quality evidence that the use of prophylactic antibiotics reduces the risk of infectious complications following third molar extraction

There is no clear evidence that timing of antibiotic administration (pre-operative, post- operative or both) is important

The numbers of healthy people undergoing third molar extraction who need to be treated with antibiotics to prevent one infection range between 10 and 17, and to prevent a case of dry socket between 24 and 250 people would need to receive prophylactic antibiotics

The size of the benefit is not enough to recommend a routine use of this practice, due to the increased risk of mild adverse effects for the patients and also the potential for contributing to the development of bacterial resistance

Cochrane Library

Cochrane Database of Systematic Reviews

Antibiotics to prevent complications following tooth extractions (Review)

Lodi G, Figini L, Sardella A, Carrassi A, Del Fabbro M, Furness S

Lodi G, Figini L, Sardella A, Carrassi A, Del Fabbro M, Furness S.
Antibiotics to prevent complications following tooth extractions.
Cochrane Database of Systematic Reviews 2012, Issue 11. Art. No.: CD003811.
DOI: 10.1002/14651858.CD003811.pub2.

www.cochranelibrary.com

Antibiotics to prevent complications following tooth extractions (Review)
Copyright © 2013 The Cochrane Collaboration. Published by John Wiley & Sons, Ltd.

WILEY

Infection

Postoperative Complications

Antibiotics are indicated in:

- Contaminated/Dirty wounds
- Medically compromised patients
- Long cases requiring extensive surgery

Antibiotics
Penicillin
Amoxicillin / Clavulanic Acid Amoxicillin
Clindamycin

Incision and Drainage (Abscess present)

Dry Socket

Postoperative Complications

1-3%
Painful condition thought to be due to premature disruption of the blood clot by increased fibrinolytic activity within the early post extraction socket. Imparing the formation of granulation tissue.

Develops on the average 3-4 days after extraction

Characterized by TRIAD:

- Early onset clot lysis
- Intense throbbing pain
- Halitosis

Not characterized by presence of fever, erythema, swelling, or pus presence

More common in women

Mandibular molars affected 10 times more compared to maxillary molars

3-4 days after extraction

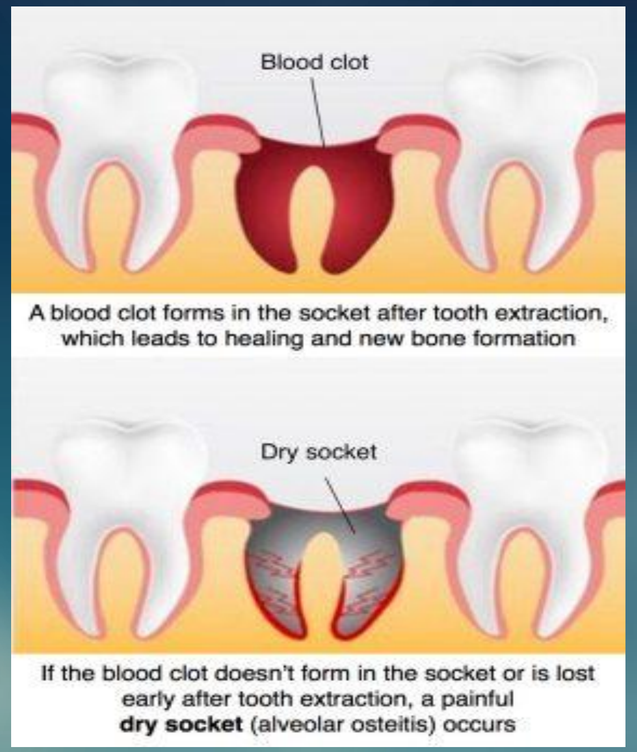

Dry Socket

Postoperative Complications

Etiology/Pathophysiology

Fact: failure of the clot to be replaced by granulation tissue
Increased local fibrinolytic activity (plasmin activated ?)
Bacterial activity leading to fibrinolysis (never proven)
Evidence of bacterial etiology is only indirect consisting of the the fact that local antimicrobials seem to reduce the incidence of it
Mechanical dislodgement of clot (coughing , sneezing, spitting sucking through straw) has been postulated – never proven

Incidence
Anywhere from 0.5% to 5% of all extractions – wide clinical criteria for diagnosis
1% to 37% for impacted wisdom teeth

Most common teeth affected: Lower molars
Second: Lower premolars-canines
Least: upper incisors

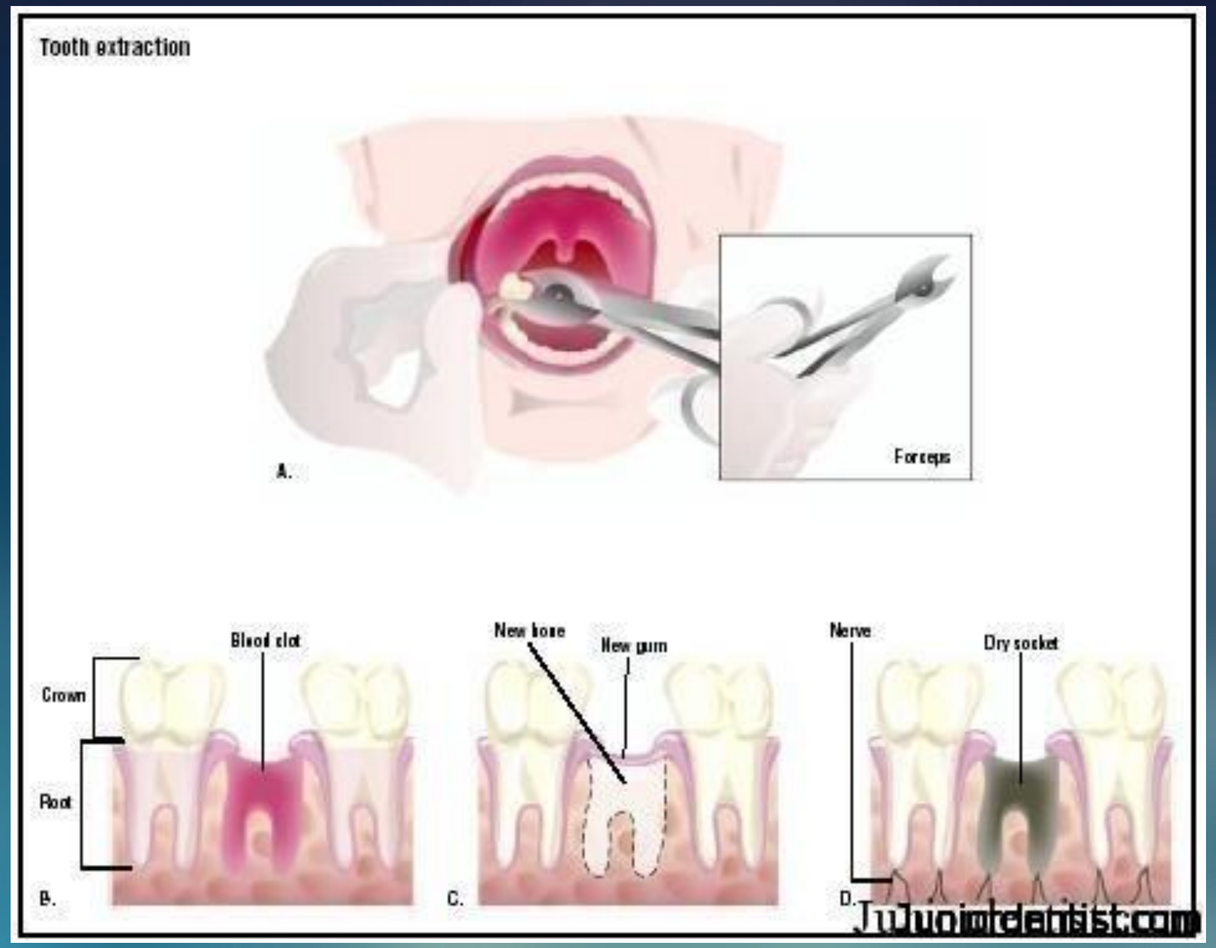

Dry Socket

Postoperative Complications

Predisposing factors

- Female gender
- Advanced age
- Oral contraceptives
- Smoking
- Increased age
- Difficult surgery/partial impaction
- Inexperienced surgeon
- Inadequate irrigation
- Preexisting infection
- History of pericoronitis
- Bad hygiene
- Poor post op aftercare
- Periodontal disease

Diagnosis
Hx: timing of symptoms, nature of pain, tooth extracted, difficulty of surgery

Clinical picture: lack of clot, bare bone walls, “junk in socket” (not necessarily swelling, trismus, fever)

Dry Socket

Postoperative Complications

ONSET:
within 3-4 days post extraction

SYMPTOMS:
debilitating throbbing pain radiating to ears, temple, neck

SIGNS:
Halitosis
Empty socket with bare bone walls sometimes full of food remnants
Possible low-grade fever
Regional lymphadenopathy
(swelling, trismus, fever not necessarily there)

DURATION
up to 7-10 days

Dry Socket

Postoperative Complications

Management

PRIMARY GOAL: Symptomatic relief of pain

- Irrigation of the socket with saline
- Packing the socket with a dressing with a carrier, eugenol packing or lidocaine jelly
- Repeat dressing every other day until patients symptoms improve
- If no resolution evaluate further for osteomyelitis

The most common being a gauze dressing medicated with
Zinc Oxide – eugenol
Topical anesthetic
BIPP (bismuth iodophorm paste)
Antibiotics (metronidazole)
Alveogyl (eugenol, and plant fibers)

They all control pain significantly
They all, being foreign bodies in the socket, delay healing
Prescription pain medications

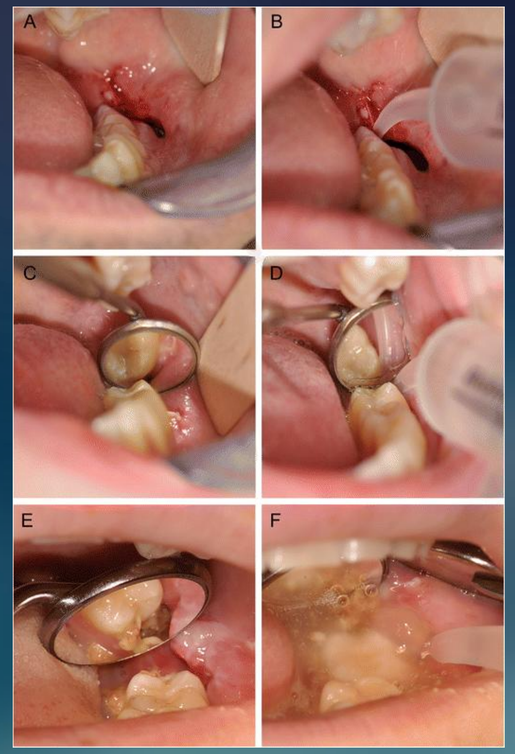

Avoid eugenol-based packings if proximity to IAN

Dry Socket

Postoperative Complications

Prevention

- Eliminate risk factors
- Intrasocket antibiotics – no conclusive evidence that they work
- Pre – post use of chlorhexidine - efficacy ?
- Intrasocket antifibrinolytics - efficacy ?
- Systemic antibiotics – efficacy?

Subperiosteal Abscess

Postoperative Complications

A soft tissue infection following the removal of lower third molars involving the area of the previously raised flap

3 weeks after removal of third molars

Hard, painful vestibular swelling in the area of the flap +/- Trismus
Mostly due to entrapment of debris under the flap
A hematoma under the flap

Management
Radiography to r/o foreign body – bone sequestrum
Surgical exploration / drainage of the area under anesthesia
Antibiotics

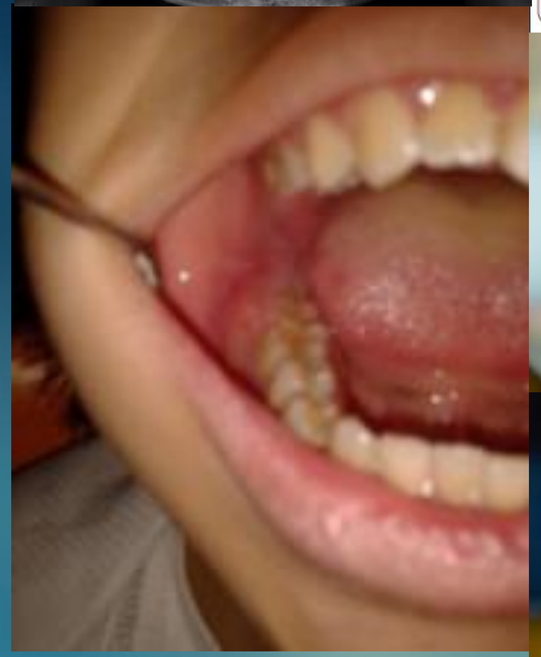

Figure 4: Review of the area in periapical view, no foreign was seen.

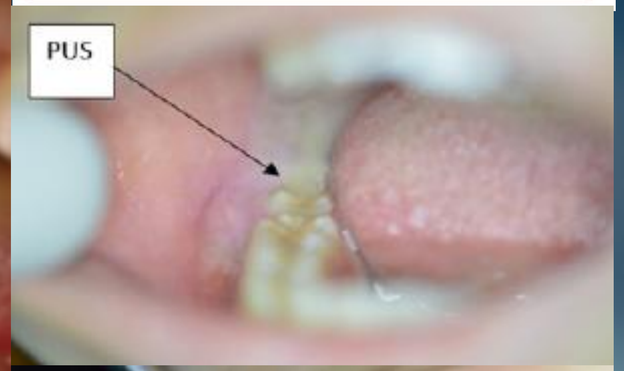

Bleeding

Postoperative Complications

Post op bleeding can be reactionary or secondary

<u>Reactionary (within first 24 hours post op)</u>

Clot formation 6-12 hours post-op
Oozing usually resolves within 36-72 hours and should respond to pressure

Occurs as a result of mechanical dislodgement of the hemostatic plug in the vast majority of cases:

- Overzealous rinsing
- Trauma
- Spitting
- Smoking
- Chewing hard food
- Vomiting
- Increased intraluminal pressure
- Vasoconstrictor degradation
- Left over granulation tissue
- Anticoagulation medication

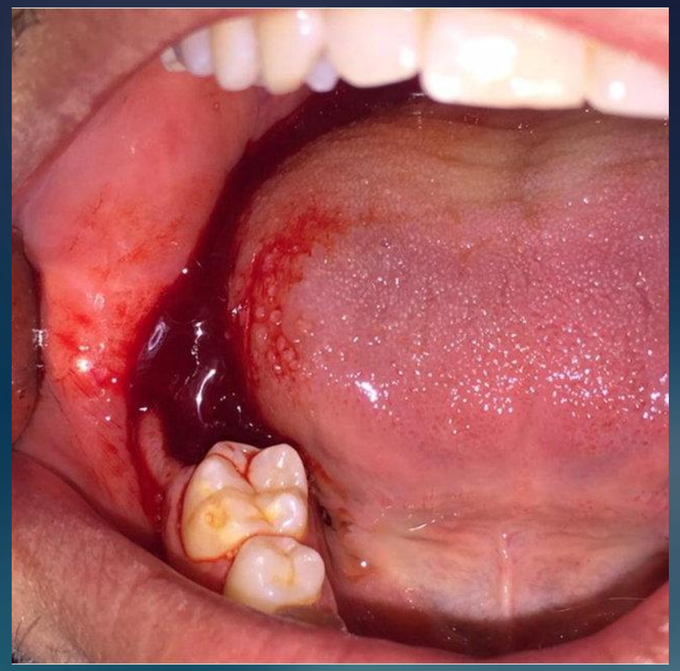

In a few patients it might be due to unrecognized before coagulation disorder, or systemic disease

Bleeding

Postoperative Complications

Post op bleeding can be:

<u>Secondary (develops after the first 24 hours)</u>

This occurs as a result of failure of the hemostatic plug and the healing process in the vast majority of cases:

- Infection
- Trauma
- Nonspecific fibrinolytic activity

If "liver clot" present careful removal is needed to control bleeding

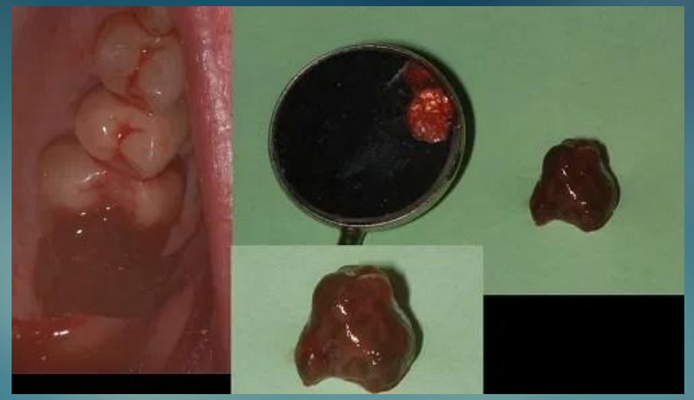

Bleeding

Postoperative Complications

Prevent:

Apply pressure

Get an idea as to the amount of blood lost
- Tachycardia
- Blood pressure
- Orthostatic hypotension
- Thirst

Review medical history once more

Determine source
- bone
- soft tissue

Determine vessel type
- artery
- vein

Bleeding

Postoperative Complications

Bone

Apply Pressure → Crush Bone If Point Source → Bone Wax → Hemostatic Agents

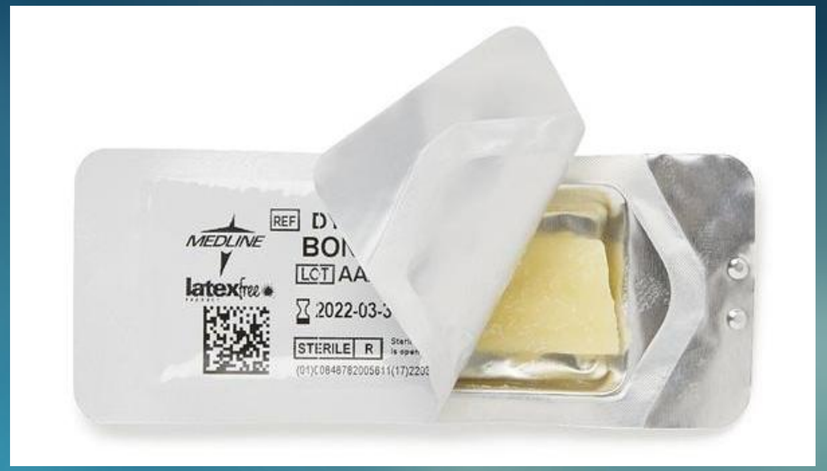

Bleeding

Postoperative Complications

Soft Tissue

Apply Pressure → Identify Vessel → Cauterize / Ligate → Apply warm pack if generalized → Hemostatic Agents → Fribrin Sealant

Prevention

- Avoiding flap tears
- Primary wound closure
- Topical agents: Gelfoam and Surgicel

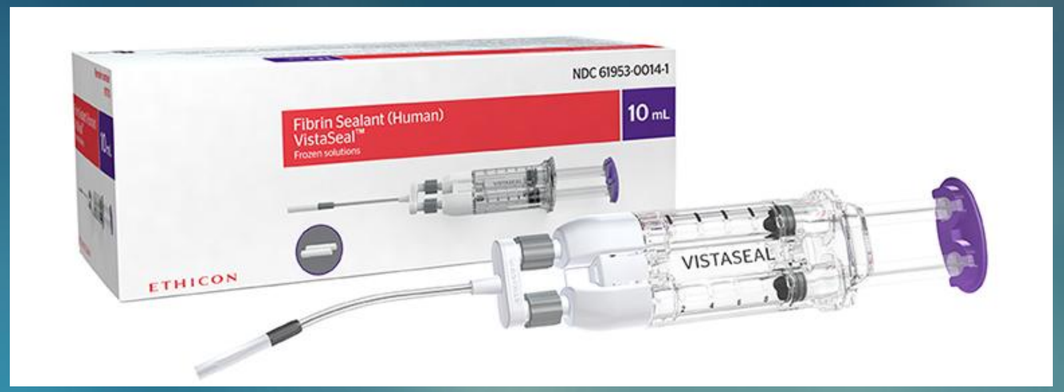

Neurological Complications

Postoperative Complications

Haug et al. The AAOMS Age-Related Third Molar Study. J Oral Maxillofac Surg, 63: 1106, 2005

L. K. Cheung, Y. Y. Leung, L. K. Chow, M. C. M. Wong, E. K. K. Chan, Y. H. Fok:
Incidence of neurosensory deficits and recovery after lower third molar surgery: a prospective clinical study of 4338 cases. Int. J. Oral Maxillofac. Surg. 2010; 39: 320– 326

Wassem Jerjes et all:Risk factors associated with injury to the inferior alveolar and lingual nerves following third molar surgery—revisited.
Oral Surg Oral Med Oral Pathol Oral Radiol Endod 109:335-345, 2010

	Temporary	Permanent
IAN	0.35-1.6%	0.12-0.6%
Lingual Nerve	0.2-1.8%	0.16-1.1%

Neurological Complications

Postoperative Complications

Risk Factors: Anesthesia/paresthesia of IAN

- Degree/Depth of impaction
- Need to section tooth
- Displacement of tooth into canal
- Surgical transection
- Experience of the operator - postoperative hematoma
- Length of surgery – postoperative edema
- Age of patient
- Chemical injury
- Trauma from block injection (1 in 785.000 cases, 21% involve IAN)

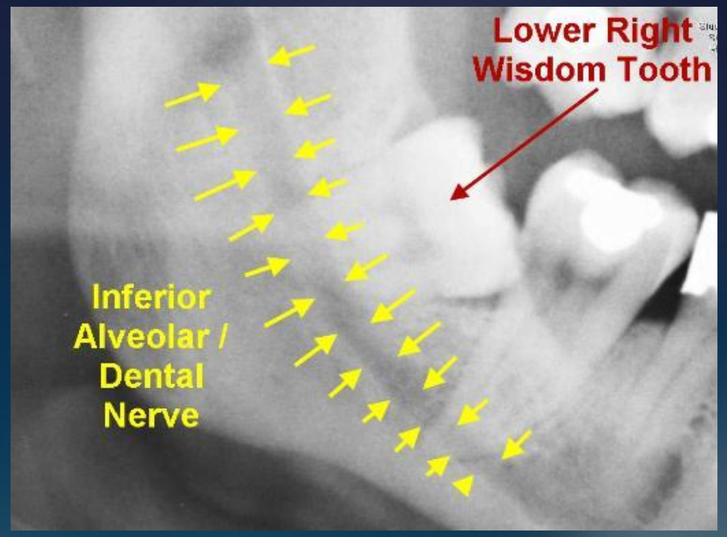

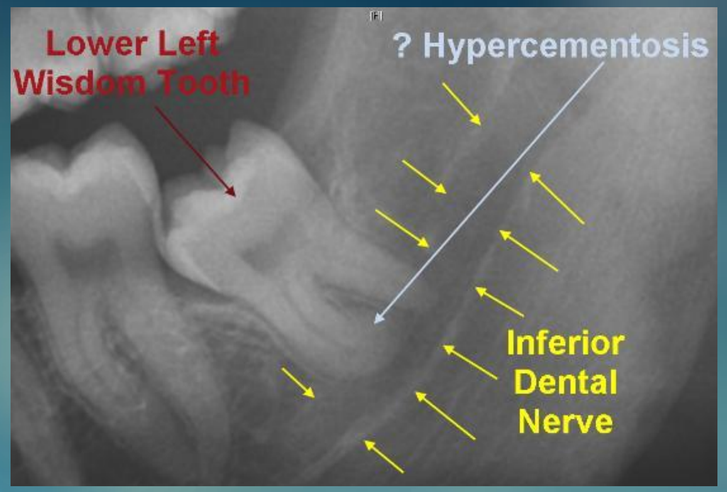

Rood and Shehab's radiographic features

Proximity to IAN canal
Radiographic predictors (panoramic view)

- Diversion of the canal
- Narrowing of the canal
- Interruption/Lack of cortical line
- Deflection of the roots
- Darkening of the roots
- Narrowing of the roots

CBCT imperative today to determine true relationship and specific risk assessment

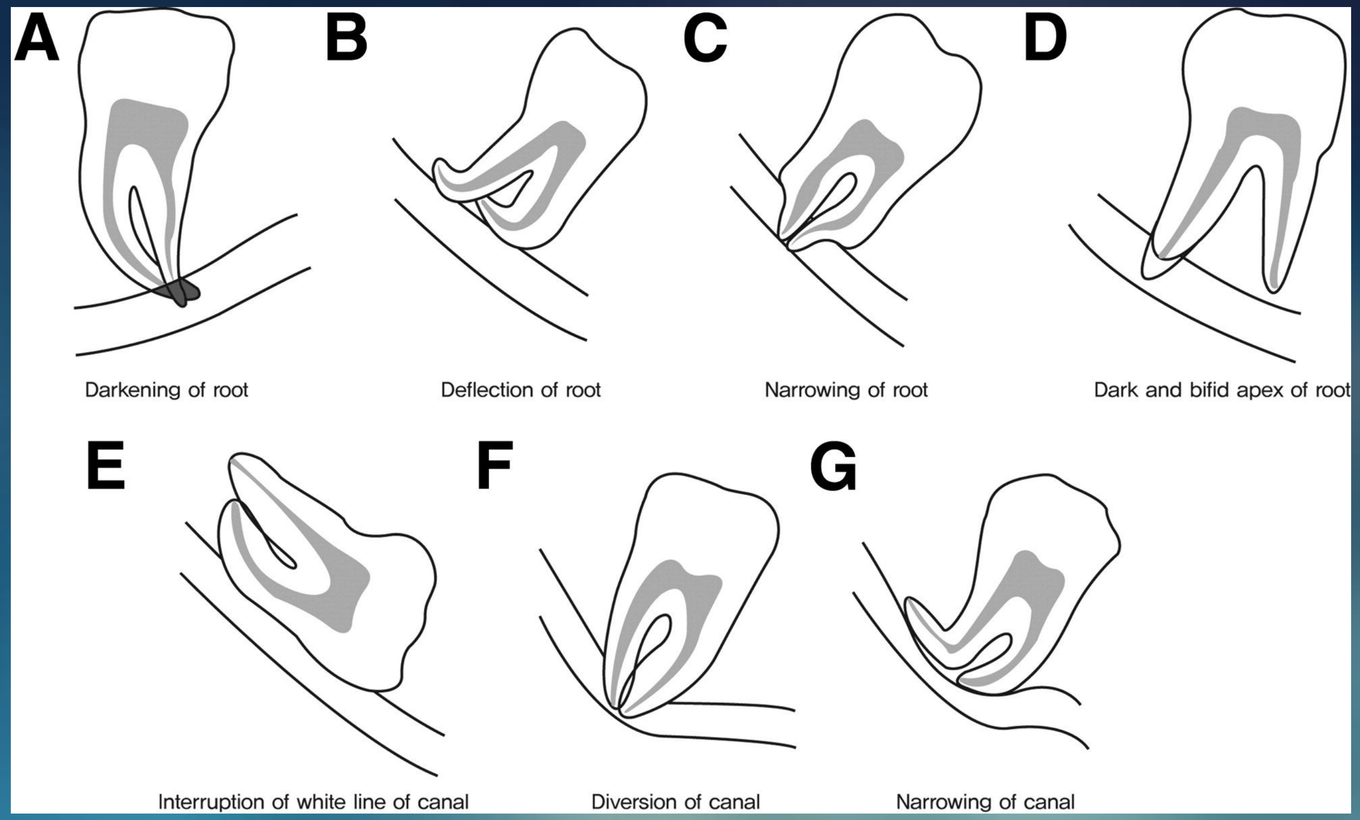

Neurological Complications

Postoperative Complications

Anesthesia/paresthesia of LN
(runs in soft tissue/not visible radiographically)
Positioned above lingual crest in 14% of cases
Distance to lingual crest: H-2.1mm, V-3mm
Lingual plate in direct contact with the nerve in 86% of cases

Risk Factors:

- Lingual orientation of third molar
- Preexisting lingual plate perforation
- Lingual flap reflection – traction injury
- Lingual plate fracture during surgery
- Agressive curettage of folicular sac or granulation tissue
- Deeply placed lingual sutures
- Surgical transection
- Wrong incision / flap planning
- Trauma from block injection (1 in 785.000 cases, 79% involve LN) It is morst common in lingual nerve and 80-88% resolve within one week

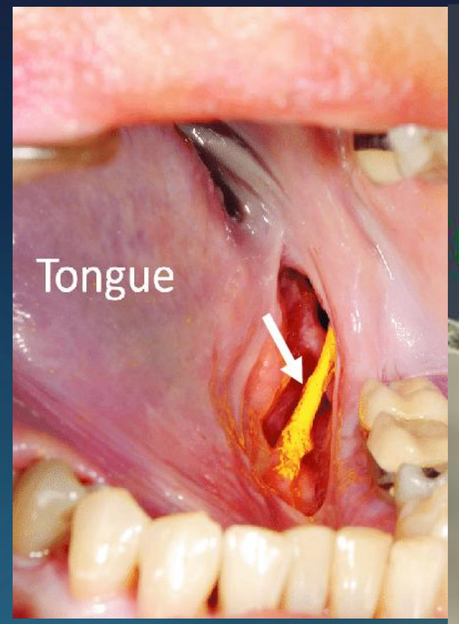

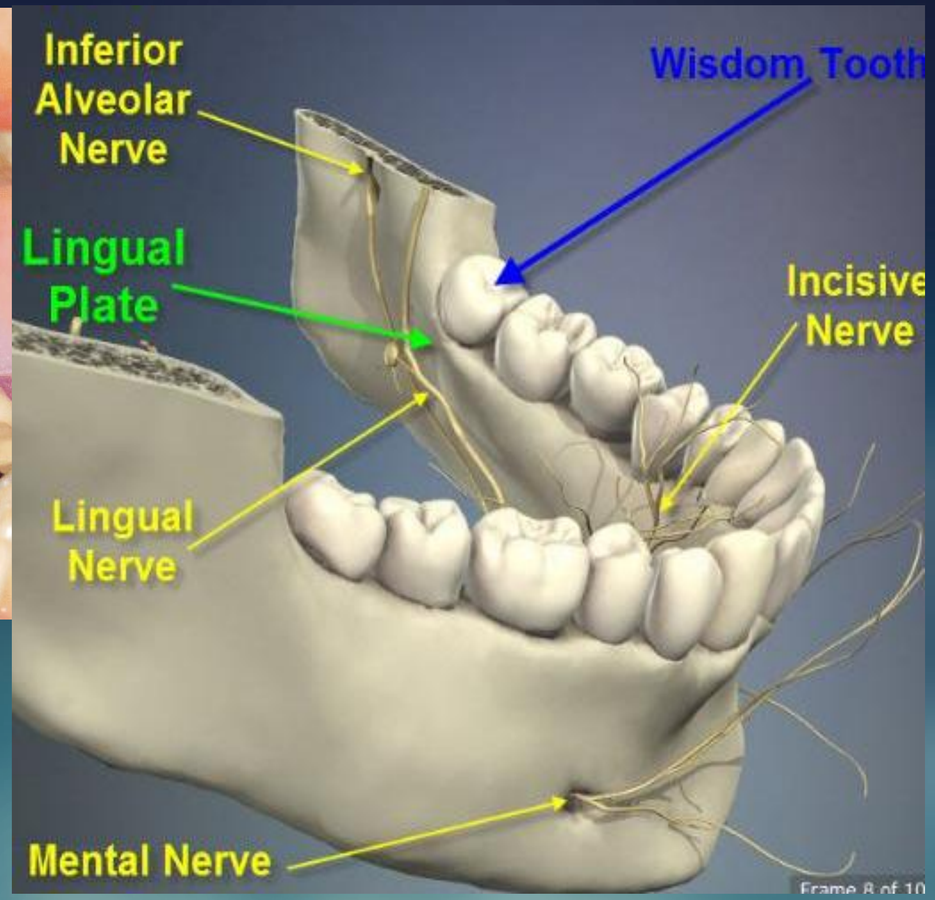

Neurological Complications

Postoperative Complications

Management
Close follow up of the patient till resolution

Neurosensory testing/mapping of affected area
Mechanoreceptive testing
Two-point discrimination
Static light touch
Brush stroke
Vibration sense
Nociceptive testing
Pain prick (pin pressure)
Thermal discrimination

Start peripherally and proceed centrally

FIGURE 2: Pain (pin-prick) perception.

FIGURE 3: Two-point discrimination threshold.

FIGURE 5: Directional sense

FIGURE 6: Pointed dull discrimination

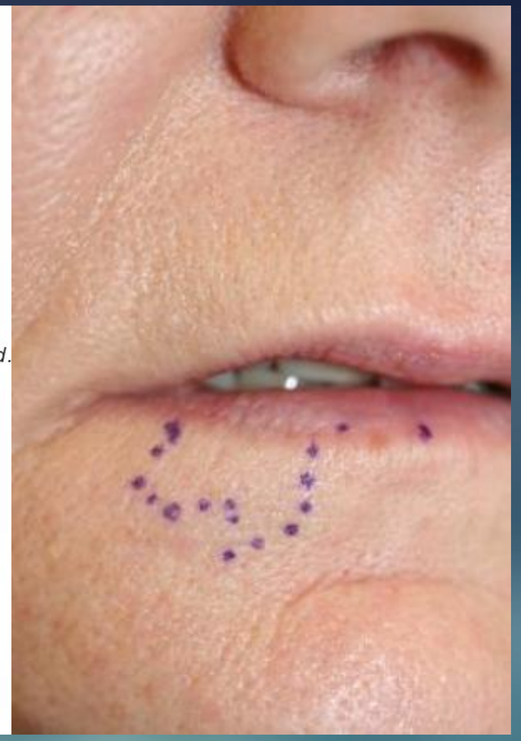

Neurological Complications

Postoperative Complications

Neurosurgical repair: indicated in persistent parestesia that fails to improve over several examinations over 4 weeks or if observed transection

Lingual nerve 1-3months
IAN 3-6months
If compression injury (Tooth, fragment removal, implant removal) immediate decompression is needed
Chemical injuries (root canal sealant) should be debrided immediately
Avulsive injury delayed 3 weeks because it allows demarcation of injury

Surgical technique: Microneurosurgery
Overall recovery rates 51-80% Lingual nerve most successful
Exposure of the nerve
Decompression and examination of nerve
Prepare nerve stumps for repair – neuroma resection

Neurorrhaphy: sutures in epinerium, tensión free – best outcomes
Nerve grafts: Sural Nerve, Greater Auricular – less than 50% improvement
Entubation or nerve conduit

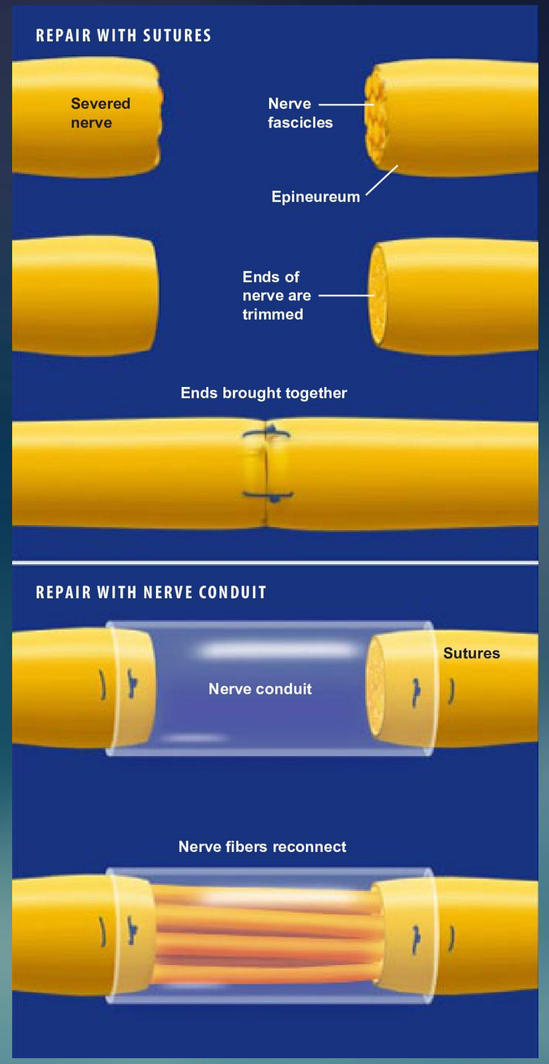

Neurological Complications

Postoperative Complications

Nerve regeneration occurs at approximately 1mm/day from the cell body

Prevention:

- Proper preoperative planning
- Proper intraoperative techniques
- Anesthetic techniques
- Advanced imaging techniques
- Consideration of coronectomy if high risk

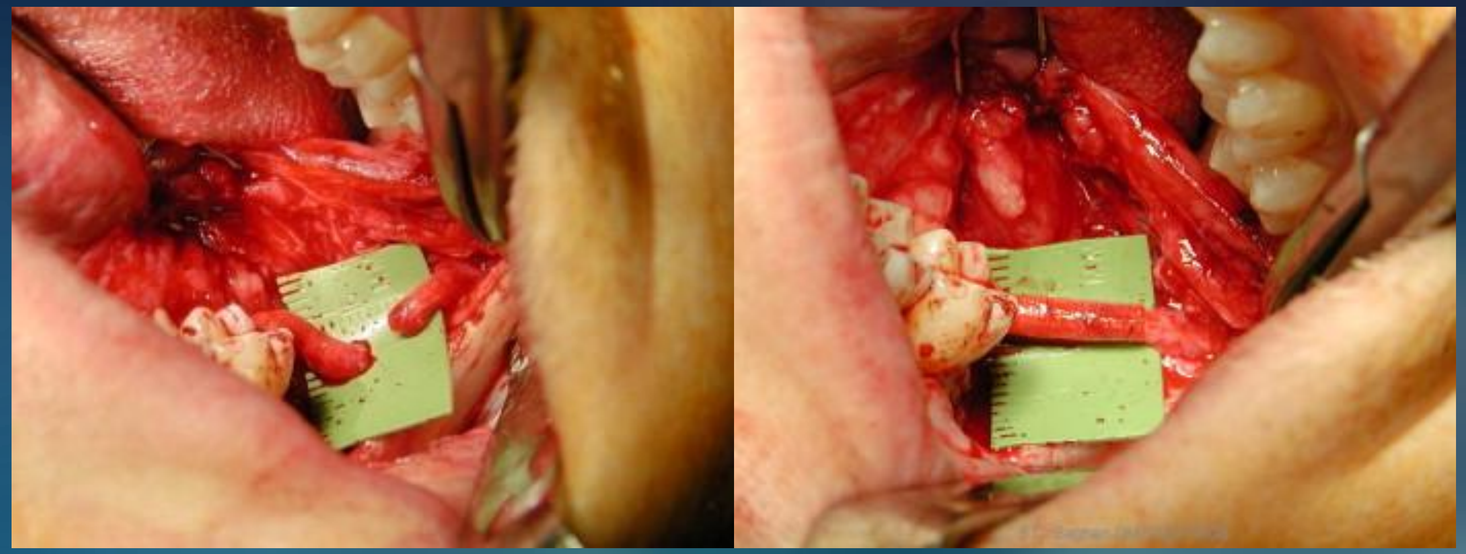

TMJ Pain

Postoperative Complications

Causes:

- Prolonged mouth opening
- Streching
- Lack of support of the mandible during surgery
- Pressure on the joint contralateral to the side where mandibular surgery is performed

Prevention

Document pre-existing TMJ symptoms

Mouth prop/bite block

Intraoperative mandibular support

If dislocation occurs: reduce immediately

Management:

Soft diet, warm compresses, jaw rest, NSAIDs, re-evaluate

Ongoing symptoms may require MRI evaluation

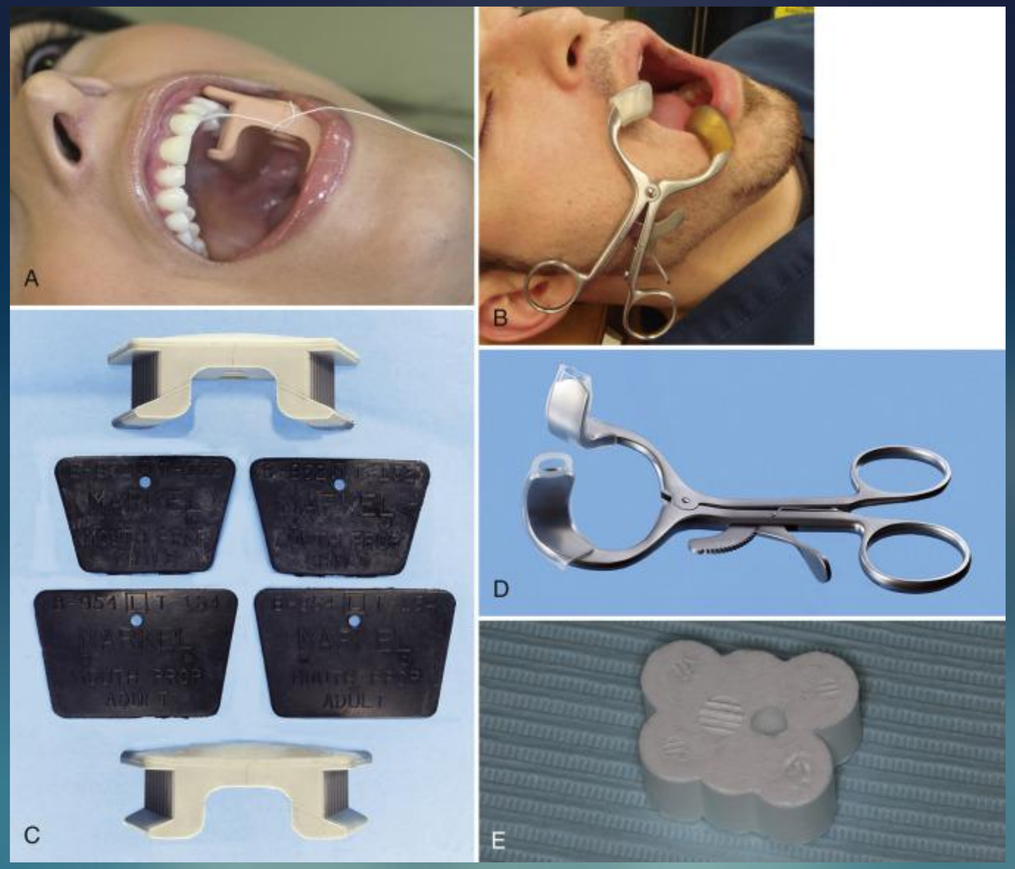

Thank you

Maria Franco Echevarria, MD, DMD, MSc, FRCDC
Assistant Professor. Undergraduate Program Co-Director
Oral and Maxillofacial Surgery

Faculty of Dentistry
University of Toronto
maria.francoechevarria@utoronto.ca

References Intraop

1. http://nhakhoahd.com/cham-soc-sau-nho-rang/
2. Tác giả Dr. Duy Nguyen. (2019, November 8). Chăm Sóc sau nhổ Răng. hd Dental Clinic. http://nhakhoahd.com/cham-soc-sau-nho-rang/.
3. Tewari, Nitesh & Bansal, Kalpana & Mathur, Vijay. (2019). Dental Trauma in Children: A Quick Overview on Management. The Indian Journal of Pediatrics. 86. 10.1007/s12098-019-02984-7.
4. Self oral cancer screening. LSU Health New Orleans. (n.d.). https://www.lsusd.lsuhsc.edu/socs/.
5. Wikimedia Foundation. (2020, July 1). Infratemporal fossa. Wikipedia. https://en.wikipedia.org/wiki/Infratemporal_fossa.
6. Volker, D. J. H. (2018, August 30). Maxillary sinus. Earth's Lab. https://www.earthslab.com/anatomy/maxillary-sinus/.
7. Twittercreator. (n.d.). Nicolas Homsi. AO Foundation Surgery Reference. https://surgeryreference.aofoundation.org/cmf/trauma/mandible/further-reading/anatomy#nerves-sensory-nerves-branches-of-the-mandibular-nerve-cn-v3-.
8. Kocaelli, H., Balcioglu, H. A., & Erdem, T. L. (2011). Displacement of a maxillary third molar into the buccal space: anatomical implications apropos of a case. International journal of oral and maxillofacial surgery, 40(6), 650–653. https://doi.org/10.1016/j.ijom.2010.11.021
9. Shruthi, T. M., Shetty, A., Imran, M., Akash, K. S., Ahmed, F., & Ahmed, N. (2020). Removal of Displaced Maxillary Third Molar Using Modified Gillie's Temporal Approach. Annals of maxillofacial surgery, 10(1), 210–212. https://doi-org.myaccess.library.utoronto.ca/10.4103/ams.ams_254_19
10. Lawson, W., Patel, Z. M., & Lin, F. Y. (2008). The development AND Pathologic processes that INFLUENCE maxillary Sinus pneumatization. The Anatomical Record: Advances in Integrative Anatomy and Evolutionary Biology, 291(11), 1554–1563. https://doi.org/10.1002/ar.20774
11. Allen, D. Z., Sethia, R., Hamersley, E., & Elmaraghy, C. A. (2020). Presentation of an iatrogenically displaced third molar into the maxillary sinus in a 14-year-old patient successfully removed with an endoscopic approach: a case report and a review of the literature. Journal of surgical case reports, 2020(10), rjaa290. https://doi-org.myaccess.library.utoronto.ca/10.1093/jscr/rjaa290
12. Wang, H., Yang, C. Y., & Li, Z. (2018). Traumatic displacement of teeth into maxillary sinus and the retrieval assisted by computer-assisted navigation: A case report. Medicine, 97(51), e13865. https://doi.org/10.1097/MD.0000000000013865
13. Caldwell-Luc / Intra-oral Antrostomy. Exodontia. (2021, July 19). https://exodontia.info/caldwell-luc-operation-intra-oralantrostomy/.
14. Jolly, S. S., Rattan, V., & Rai, S. K. (2014). Intraoral management of displaced root into submandibular space under local anaesthesia -A case report and review of literature. The Saudi dental journal, 26(4), 181–184. https://doi-org.myaccess.library.utoronto.ca/10.1016/j.sdentj.2014.05.004
15. Andreia Yad ., PissedConsumer1678230, Djz, E., PissedConsumer1363649, & PissedConsumer1362484. (2019, July 7). Western dental - cut my outer lip inside and out Jul 07, 2019 @ pissed consumer. Pissed Consumer. Retrieved November 30, 2021, from https://western-dental.pissedconsumer.com/cut-my-outer-lip-inside-and-out-201708161088580.html.
16. Smith, J. (2017, June 2). Man threatening to sue dentist after she 'scarred him for life'. BristolLive. Retrieved November 30, 2021, from https://www.bristolpost.co.uk/news/bristol-news/man-threatening-sue-dentist-after-87371.
17. Tooth extraction is last resort when treating an infected/damaged tooth. Dentist in Chandler, AZ | Local Dentist for You & Your Family. (2021, June 4). Retrieved November 30, 2021, from https://impressionsdental.com/tooth-extraction/.
18. Loading. glidewelldental.com. (n.d.). Retrieved November 30, 2021, from https://glidewelldental.com/education/chairside-dental-magazine/volume-2-issue-2/when-is-a-full-crown-restoration-indicated/.
19. Root fractures in the posterior jaw, deep apical. Benex. (n.d.). Retrieved November 30, 2021, from https://www.benex-dent.com/en/benex-extraktor/clinical-application/root-fracture-posterior-maxilla-deep-apical/.
20. Cai, Y., Sun, R., & Zhao, J. H. (2018). Flapless boning to increase space by piezosurgery: A novel mini-invasive strategy for teeth extraction. A retrospective study. Medicine, 97(27), e11398. https://doi-org.myaccess.library.utoronto.ca/10.1097/MD.0000000000011398
21. Hupp ,Tucker, Ellis Contemporary Oral and Maxillofacial Surgery 2013
22. Ethunandan, M., Shanahan, D. & Patel, M. Iatrogenic mandibular fractures following removal of impacted third molars: an analysis of 130 cases. Br Dent J 212, 179–184 (2012). https://doi.org/10.1038/sj.bdj.2012.135
23. Fracture of mandible angle and Ramus. (n.d.). Retrieved November 30, 2021, from https://ltsale.2021onlines.com/category?name=fracture+of+mandible+angle+and+ramus.
24. HaThuy. (2019, July 28). Bleeding after wisdom teeth extraction, is it normal? Trang Chủ Mới -. Retrieved November 30, 2021, from http://nhakhoaquocbinh.com/en/bleeding-after-wisdom-teeth-extraction/.
25. Review of Hemostatic agents used in dentistry. Dentistry Today. (2005, March 1). Retrieved November 30, 2021, from https://www.dentistrytoday.com/sp-1459248816/.
26. Sterile Natural Bone Wax. ModoMed. (n.d.). Retrieved November 30, 2021, from https://www.modomed.com/cgi-bin/frontrunner.cgi?ri=100&rc=MODO&rs=&ro=T&pln=MS&pid=MSOB&pm=OR%2BBasics&sid=DYNJBW25&msds=Sterile%2BNatural%2BBone%2BWax&in=DYNJBW25&bu=0&ki=&os=AUTOCAST&ctc=1.
27. Fractured maxillary tuberosity. Exodontia. (2021, July 19). Retrieved November 30, 2021, from https://exodontia.info/fractured-maxillary-tuberosity/.
28. The level One: Maxillary sinus - North Dakota Dental ...(n.d.). Retrieved November 30, 2021, from https://www.smilenorthdakota.org/docs/librariesprovider39/north-dakota/70-sinus-and-extractions-(copyright-dr-karl-koerner-aug-2017).pdf?sfvrsn=2.

References Postop

1. HENNY F. A. (1947). Postoperative infection and hemorrhage after extraction of third molar. Journal of oral surgery, 5(3), 208.
2. Yilmaz, S., Bas, B., Ozden, B., Selcuk, U., & Cengel Kurnaz, S. (2015). Deep neck infection after third molar extraction. Journal of Istanbul University Faculty of Dentistry, 49(2), 41–45. https://doi-org.myaccess.library.utoronto.ca/10.17096/jiufd.82633
3. Operculectomy. (2021, July 19). Retrieved December 12, 2021, from https://exodontia.info/operculectomy/
4. Jevon, P., Abdelrahman, A., & Pigadas, N. (2020). Management of odontogenic infections and sepsis: an update. British dental journal, 229(6), 363–370. https://doi-org.myaccess.library.utoronto.ca/10.1038/s41415-020-2114-5
5. Lodi, G., Figini, L., Sardella, A., Carrassi, A., Del Fabbro, M., & Furness, S. (2012). Antibiotics to prevent complications following tooth extractions. The Cochrane database of systematic reviews, 11, CD003811. https://doi-org.myaccess.library.utoronto.ca/10.1002/14651858.CD003811.pub2
6. Wisdom tooth extraction (removal). (2019, June 24). Retrieved December 12, 2021, from https://www.pacificoralsurgeon.com/wisdom-tooth-extraction/
7. Dry socket. (2021, July 19). Retrieved December 12, 2021, from https://exodontia.info/dry-socket/
8. Garola, F., Gilligan, G., Panico, R., Leonardi, N., & Piemonte, E. (2021). Clinical management of alveolar osteitis. A systematic review. Medicina oral, patologia oral y cirugia bucal, 26(6), e691–e702. https://doi-org.myaccess.library.utoronto.ca/10.4317/medoral.24256
9. Ghaeminia, H., Hoppenreijs, T. J., Xi, T., Fennis, J. P., Maal, T. J., Bergé, S. J., & Meijer, G. J. (2017). Postoperative socket irrigation with drinking tap water reduces the risk of inflammatory complications following surgical removal of third molars: a multicenter randomized trial. Clinical oral investigations, 21(1), 71–83. https://doi-org.myaccess.library.utoronto.ca/10.1007/s00784-016-1751-1
10. Library, D. (n.d.). Alvocure dry socket dental treatment - stock image - C047/6067. Retrieved December 12, 2021, from https://www.sciencephoto.com/media/1063265/view/alvocure-dry-socket-dental-treatment
11. Dry socket pictures: Pictures of Alveolar Osteitis. Retrieved December 12, 2021, from https://www.juniordentist.com/dry-socket-pictures.html
12. Tim, D. (2021, March 22). Dry socket after wisdom tooth extraction: How to prevent. Retrieved December 12, 2021, from https://impactedwisdom.com/dry-socket-after-wisdom-tooth-extraction-removal.html
13. Dental nerve injuries. (2021, July 19). Retrieved December 12, 2021, from https://exodontia.info/dental-nerve-injuries/
14. Kim, J. W., Cha, I. H., Kim, S. J., & Kim, M. R. (2012). Which risk factors are associated with neurosensory deficits of inferior alveolar nerve after mandibular third molar extraction?. Journal of oral and maxillofacial surgery : official journal of the American Association of Oral and Maxillofacial Surgeons, 70(11), 2508–2514. https://doi-org.myaccess.library.utoronto.ca/10.1016/j.joms.2012.06.004
15. Lingual nerve in the left lower third molar area (arrow ... (n.d.). Retrieved December 12, 2021, from https://researchgate.net/figure/Lingual-nerve-in-the-left-lower-third-molar-area-arrow_fig1_334302050
16. Digital Nerve Repair. (2021, November 20). Retrieved December 12, 2021, from https://www.orthoriverside.com/education/digital-nerve-repair/
17. Lingual Plate fracture. (2021, October 26). Retrieved December 12, 2021, from https://exodontia.info/lingual-plate-fracture/
18. Bagheri, S. C., Meyer, R. A., Khan, H. A., Kuhmichel, A., & Steed, M. B. (2010). Retrospective review of microsurgical repair of 222 lingual nerve injuries. Journal of oral and maxillofacial surgery : official journal of the American Association of Oral and Maxillofacial Surgeons, 68(4), 715–723. https://doi-org.myaccess.library.utoronto.ca/10.1016/j.joms.2009.09.111
19. Mahon, N., & Stassen, L. (1970, January 01). Figure 1 from post-extraction inferior alveolar nerve neurosensory disturbances--a guide to their evaluation and practical management.: Semantic scholar. Retrieved December 12, 2021, from https://www.semanticscholar.org/paper/Post-extraction-inferior-alveolar-nerve-guide-to-Mahon-Stassen/45c34b34a4422cc94ded1438cf623edd84b89325/figure/1
20. Mouth prop. (n.d.). Retrieved December 12, 2021, from https://www.sciencedirect.com/topics/medicine-and-dentistry/mouth-prop
21. Wei, M., & Mahdey, H. (2019, January 23). Dissecting subperiosteal abscess after surgical removal of mandibular third molar. Retrieved December 12, 2021, from https://irispublishers.com/ojdoh/fulltext/dissecting-subperiosteal-abscess-after-surgical-removal-of-mandibular-third-molar.ID.000518.php
22. Severe bleeding after extraction of the second mandibular ... (n.d.). Retrieved December 12, 2021, from https://researchgate.net/figure/Severe-bleeding-after-extraction-of-the-second-mandibular-molar-in-a-patient-receiving_fig2_333172097
23. Bauer, B. (2019, February 14). Liver clot after dental implant surgery. Retrieved December 12, 2021, from https://www.bauersmiles.com/2015/08/liver-clot.html/
24. After tooth extraction schererville in. (n.d.). Retrieved December 12, 2021, from https://www.jplattdds.com/surgical-instructions/extractions/
25. Sutures for your clinic. (n.d.). Retrieved December 12, 2021, from https://www.sutureonline.com/bone-wax-2-5g-12-pcs
26. Editors, M. (2019, December 04). Medgadget. Retrieved December 12, 2021, from https://www.medgadget.com/2019/12/vistaseal-fibrin-sealant-to-quickly-stop-surgical-bleeds.html